

УДК 617.58-005.4-036.11-089.844+616.98+616.13-008.64+615.273.53+578.834.1
DOI: 10.56871/RBR.2023.44.71.009

COVID-19 У ПАЦИЕНТОВ С ОСТРОЙ ИШЕМИЕЙ КОНЕЧНОСТЕЙ

© Аршед Ахмад Кучай^{1, 2}, Александр Николаевич Липин^{2, 3}, Наталья Рафаиловна Карелина¹, Никита Николаевич Груздев², Кирилл Александрович Ахмадзас², Линард Юрьевич Артюх¹, Ольга Юрьевна Смирнова¹, Анна Валерьевна Зайцева¹

¹ Санкт-Петербургский государственный педиатрический медицинский университет. 194100, г. Санкт-Петербург, ул. Литовская, 2

² Городская больница № 14. 198099, г. Санкт-Петербург, ул. Косинова, 19/9

³ Военно-медицинская академия им. С.М. Кирова. 194044, г. Санкт-Петербург, ул. Академика Лебедева, 6

Контактная информация: Аршед Ахмад Кучай — врач сердечно-сосудистый хирург, клинический исследователь Городского центра спасения конечностей, старший преподаватель кафедры анатомии человека СПбГПМУ. E-mail: drarshedcvs@gmail.com
ORCID ID: 0000-0002-7974-9369

Для цитирования: Кучай А.А., Липин А.Н., Карелина Н.Р., Груздев Н.Н., Ахмадзас К.А., Артюх Л.Ю., Смирнова О.Ю., Зайцева А.В. COVID-19 у пациентов с острой ишемией конечностей // Российские биомедицинские исследования. 2023. Т. 8. № 3. С. 69–75. DOI: <https://doi.org/10.56871/RBR.2023.44.71.009>

Поступила: 19.05.2023

Одобрена: 06.07.2023

Принята к печати: 21.09.2023

Резюме. Острую ишемию конечностей можно определить как резкое снижение артериальной перфузии конечности с угрозой ее жизнеспособности. Коронавирусная инфекция 2019 года (COVID-19) вызвана тяжелым острым респираторным синдромом коронавируса 2. Она объявлена Всемирной организацией здравоохранения глобальной пандемией. Было показано, что инфекция SARS-CoV-2 имеет широкий спектр клинических проявлений: от бессимптомного течения у большого процента пациентов до легочной недостаточности, сепсиса и смерти. Пациенты с COVID-19 имеют нарушения показателей свертываемости крови и склонны к тромбозам, тромбоэмболическим осложнениям. Это состояние гиперкоагуляции, вызванное COVID-19, в основном проявляется как венозная тромбоэмболия. Поражение периферических артерий встречается реже. Представляем три случая спонтанной острой ишемии конечностей у пациента с COVID-19.

Ключевые слова: острая ишемия конечностей; коронавирусная болезнь 2019; низкомолекулярный гепарин; коронавирус-2 с тяжелым острым респираторным синдромом; тромбэктомия; нефракционированный гепарин.

COVID-19 IN PATIENTS WITH ACUTE LIMB ISCHEMIA

© Arshed A. Kuchay^{1, 2}, Alexander N. Lipin^{2, 3}, Natalia R. Karelina¹, Nikita N. Gruzdev², Kirill A. Atmatzas², Linard Yu. Artyukh¹, Olga Yu. Smirnowa¹, Anna V. Zaicheva¹

¹ Saint Petersburg State Pediatric Medical University. Lithuania 2, Saint Petersburg, Russian Federation, 194100

² Limb Salvage Center, City Hospital № 14. Kosinova str., 19/9, Saint Petersburg, Russian Federation, 198099

³ Military Medical Academy named after S.M. Kirov. Akademichan Lebedeva st., 6, Saint Petersburg, Russian Federation, 194044

Contact information: Arshed A. Kuchay — cardiovascular surgeon, clinical researcher of the City Limb Salvage Center, Senior lecturer at the department of human anatomy SPbSPMU. E-mail: drarshedcvs@gmail.com ORCID ID: 0000-0002-7974-9369

For citation: Kuchay AA, Lipin AN, Karelina NR, Gruzdev NN, Atmatzas KA, Artyukh LYu., Smirnowa OYu, Zaicheva AV. COVID-19 in patients with acute limb ischemia // Russian biomedical research (St. Petersburg). 2023; 8(3): 69-75. DOI: <https://doi.org/0000000000000000>

Received: 19.05.2023

Revised: 06.07.2023

Accepted: 21.09.2023

Abstract. Introduction. Acute limb ischemia (ALI) is defined as an abrupt decrease in arterial perfusion of a limb with a threat to viability of the limb. Coronavirus disease 2019 (COVID-19) is caused by severe acute respiratory syndrome coronavirus 2, and has been declared as a global pandemic by the World Health Organization. Infection with SARS-CoV-2 has been shown

to have a wide range of clinical presentations from asymptomatic in a large percentage of patients to devastating pulmonary failure, sepsis, and death. Patients with COVID-19 have deranged blood coagulation parameters and are prone to thromboembolic events. This hypercoagulable state caused by COVID-19 mainly manifests as venous thromboembolism. Peripheral arterial involvement is less frequent. We present 3 cases of a spontaneous ALI in a COVID-19 patient. **Case.** A 62-year-old man with an insignificant past medical history presented with ALI 12 days after an initial diagnosis of COVID-19. He was on therapeutic doses of low molecular weight heparin when ischemic symptoms developed. A surgical thrombectomy was unsuccessful. He partially benefited from intravenous unfractionated heparin and iloprost infusions. He was discharged home on postoperative day 14, and is scheduled to have an amputation of the 1st toe. **Conclusions.** COVID-19 infection is associated with an increased incidence of thromboembolic events, including ALI. Even young and otherwise healthy patients may develop ALI despite the use of prophylactic anticoagulation. Management of ALI in COVID-19 patients might be harder than expected, due to the hypercoagulable state. Patients may benefit from prolonged post-operative unfractionated heparin administration.

Key words: acute limb ischemia; coronavirus disease 2019; low molecular weight heparin; severe acute respiratory syndrome coronavirus-2; thrombectomy; unfractionated heparin.

INTRODUCTION

Acute limb ischemia (ALI) is defined as an abrupt decrease in arterial perfusion of a limb with a threat to viability of the limb [1]. The clinical presentation is considered to be acute if symptom duration is less than 2 weeks [1]. The most common causes include embolism from cardiac chambers mainly associated with atrial fibrillation or acute myocardial infarction, embolism from arterial aneurysms, thrombosis of native limb arteries or vascular grafts, iatrogenic thromboembolism during vascular interventions, aortic dissection, and traumatic vascular injuries [1].

Coronavirus disease 2019 (COVID-19) is caused by severe acute respiratory syndrome coronavirus 2 (SARS-CoV-2), and has been declared as a global pandemic by the World Health Organization [2]. Several reports revealed that patients with COVID-19 have deranged blood coagulation parameters and are prone to thromboembolic events [2–5]. This hypercoagulable state caused by COVID-19 is associated with poor overall prognosis, and mainly manifests as venous thromboembolism (VTE) [4, 5]. Peripheral arterial involvement is less frequent [2, 5].

Herein we present 3 cases of a spontaneous ALI in a COVID-19 patient.

CLINICAL CASE 1

A 62-year-old man presented to the emergency room with complaints of fever, nausea, fatigue and muscle aches. His past medical history was insignificant. Body temperature was 36.7 °C, pulse rate 82 beats per minute, respiratory rate 24 breathes per minute, blood pressure 125/72 mmHg, and oxygen saturation 95%. There were bilateral diffuse fine crackles on auscultation. Laboratory findings were normal except for a D-dimer level of 670 ng/ml (normal range < 500 ng/ml) (Table 1). A computed tomography (CT) scan of the chest revealed bilateral ground-glass opacities (Fig. 1). A swab test result came back positive for COVID-19, and the patient was discharged home

on favipiravir, hydroxychloroquine and low-dose subcutaneous enoxaparin.

Five days later, he was hospitalized for worsening of respiratory symptoms. He appeared severely tachypneic with a respiratory rate of 40 breathes per minute, and dyspneic with an oxygen

Table 1

Laboratory findings at initial diagnosis (day 0), hospitalization (day 5), discharge (day 10), re-hospitalization for acute limb ischemia (day 12)

Таблица 1

Результаты лабораторных исследований при первоначальном диагнозе (0-й день), госпитализации (5-й день), выписке (10-й день), повторной госпитализации при острой ишемии конечностей (12-й день)

Parameters	Day 0	Day 5	Day 10	Day 12	Normal range
White blood cell, 10 ³ /μL	12.4	16	19.6	20.5	4–11
Neutrophil count, 10 ³ /μL	10.2	12.6	15.2	16.4	2–7
Lymphocyte count, 10 ³ /μL	1.2	1.4	1.6	2.5	1–3
Platelet count, 10 ³ /μL	269	306	422	374	100–450
Hemoglobin, g/dL	13.7	14	13.3	11	14–18
Prothrombin time, seconds	15.5	15.1	12.5	12.6	11.5–15.5
Partial thromboplastin time, seconds	23.1	26.2	23.2	22.8	23.5–35
C-reactive protein, mg/dl	0.78	15.4	7.34	13.38	<0.5
D-dimer, ng/mL	670	950	590	–	< 500
Fibrinogen, mg/dL	280	315	172	–	200–400
Lactate dehydrogenase, IU/L	109	1276	1045	–	0–250
Creatine kinase, IU/L	22	386	103	398	30–200
Serum creatinine, mg/dL	1.14	1.39	1.34	3.54	0.67–1.17

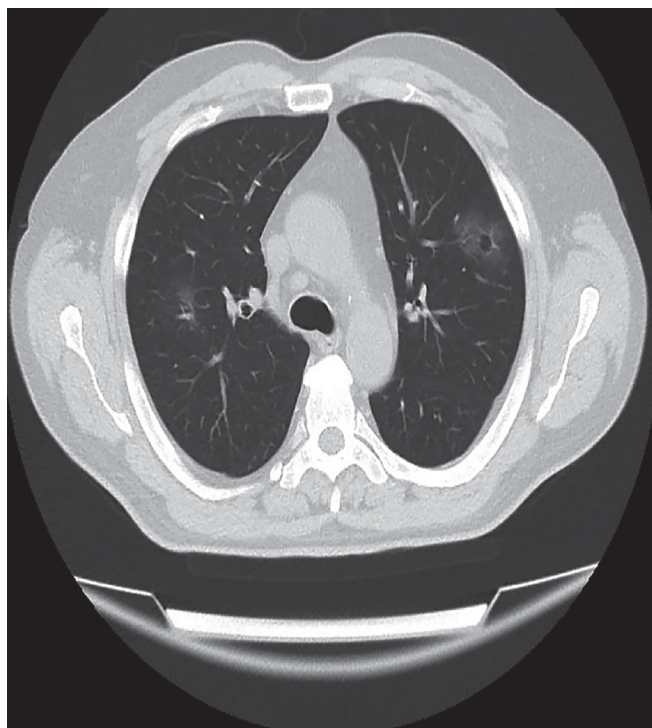
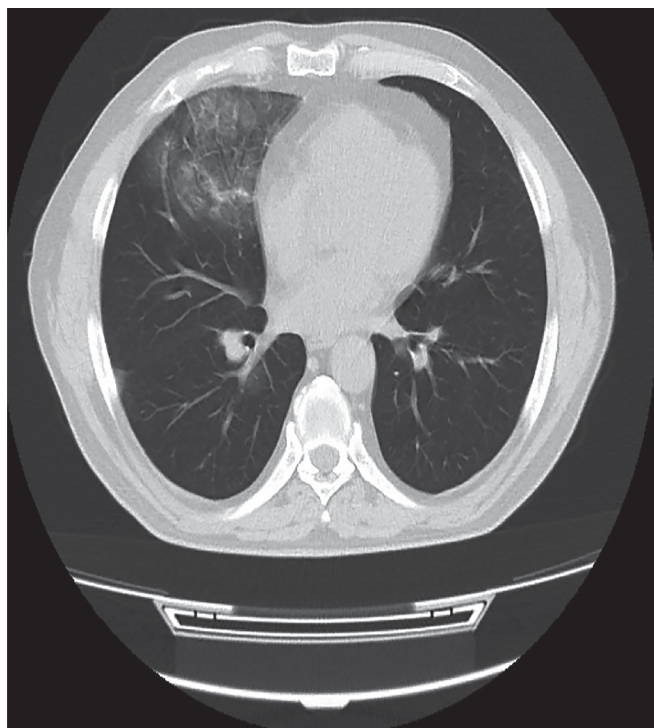


Fig. 1. Computed tomography scan of the chest demonstrating bilateral ground-glass opacities


Рис. 1. Компьютерная томография грудной клетки, демонстрирующая двустороннее просвечивание

saturation of 82% on ambient air. D-dimer level was elevated to 950 ng/ml. Low molecular weight heparin dosage was increased to therapeutic doses (enoxaparin 8000 IU twice daily). The patient was discharged home 5 days after his hospitalization with complete resolution of symptoms.

However, 2 days later, he presented to emergency room with a cold, cyanotic and painful left foot. Left pedal pulses were absent with minimal sensory loss and normal motor function. A CT angiography of the lower extremities revealed occlusion of left tibial arteries (Fig. 2). The arterial tree was free of atherosclerotic plaques, and there were no collateral vessels, suggesting an acute occlusion. Transthoracic echocardiography and thoraco-abdominal aortic imaging were negative for proximal sources of thromboembolism. 5000 IU unfractionated heparin (UFH) bolus was administered intravenously. Patient was transferred to the operating theatre for surgical intervention. Popliteal trifurcation was explored through medial infragenicular approach under local anesthesia. Popliteal artery and all of its branches appeared healthy without any atherosclerotic plaques. A longitudinal arteriotomy revealed excellent antegrade blood flow with absent retrograde flow. An attempt was made to remove the thrombus using 2 and 3F Fogarty catheters. However, the thrombus was densely organized and catheters could not be passed across the occluded segment. We did not perform thrombolysis due to organized nature of the thrombus. The arteriotomy was closed with patch plasty. Patient was transferred toward. Intravenous UFH and iloprost infusions were started. Heparin dose was adjusted to maintain an activated clotting time (ACT) of 200–250 seconds. Continuous iloprost infusion was maintained until discharge. The ischemic foot improved significantly with systemic

Fig. 2. Computed tomography angiography of the left lower extremity demonstrating occlusion of left tibial arteries, 3-dimensional reconstruction

Рис. 2. Компьютерная томография ангиографии левой нижней конечности, демонстрирующая окклюзию левой большеберцовой артерии, трехмерная реконструкция



anticoagulation, and posterior tibial and dorsalis pedis arterial Doppler signals became audible on postoperative 2nd day. However, 1st and 2nd toes and medial aspect of the foot became cyanotic again on postoperative day 5, while the ACT was within the target range (Fig. 3). Posterior tibial artery pulse was once again absent. A more than two fold increase of serum creatinine was observed following the initial CT angiography therefore a repeat angiography was not performed (Table 1). A duplex ultrasound of the lower leg performed prior to discharge revealed biphasic flow pattern in anterior tibial artery, and no flow in peroneal and posterior tibial arteries. The patient was discharged home with dry gangrene of the 1st toe on postoperative day 14 on enoxaparin 8000 IU twice daily and dual anti-platelet therapy with aspirin and clopidogrel. His condition remains stable 1 month after discharge, and a digital amputation is scheduled.

CLINICAL CASE 2

Patient G., 79 years old. Admitted with pain at rest in the left lower limb, with the presence of necrotic ulcer of the 1st finger of the left foot.

Anamnesis: Considers herself ill from more than a year, when pain first appeared in the left lower limb, an ulcer formed in the area of the first finger of the left foot. The patient received conservative treatment, no effect. Worsening in late March 2023, increasing pain syndrome, progressing necrosis of the 1st finger of the left foot.

Date of admission in the hospital: 29.03.2023. The patient was investigated. CT-angiography reports shows: occlusion of tibial arteries of the left lower limb (Fig. 4).

18.04.2023 — Balloon angioplasty of the tibial arteries of the left lower limb (Fig.5).

CLINICAL CASE 3

Patient S., 90 years old. Admitted with pain at rest in the right lower limb, with the presence of black necrosis on the fingers of the right foot.

Anamnesis: The patient has been ill from the last two months, when these complaints came in. She approached to clinic affiliated with her residence, she got treatment by conservative therapy. The conservative therapy was without effect.

Date of admission in the hospital: 20.03.2023. The patient was investigated. CT-angiography report shows: occlusion of SFA from proximal/3, Pop artery stenosis 75%, the distal/3 part of Pop artery is occlusive, anterior tibial artery is occlusive, peroneal artery, posterior tibial artery with CTO stenoses up to 90% in right lower limb (Fig. 6).

04.04.2023 — Balloon angioplasty of arteries in right lower limb (Fig. 7).

DISCUSSION

Present report describes a case of ALI in a patient with confirmed COVID-19 infection. The patient was otherwise healthy and did not have any conventional risk factors for ALI. However, his condition was resistant to treatment, and tended to recur. This finding is in correlation with reports by others [2, 6–8]. Bellosta and colleagues [6] described 20 patients (18 men) with COVID-19-associated ALI

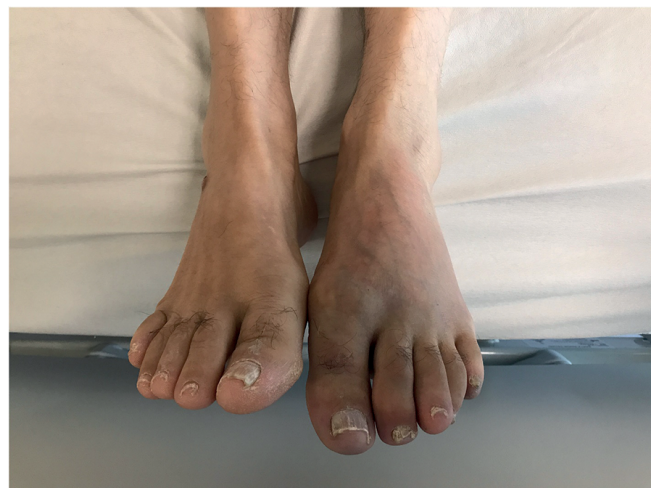

Fig. 3. Recurrent ischemia of the left foot
Рис. 3. Рецидивирующая ишемия левой ноги

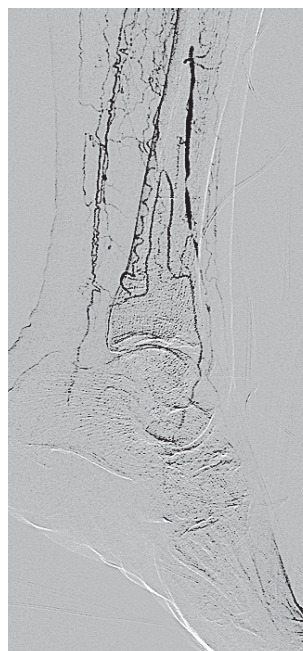

Fig. 4. Initial (before operation)
Рис. 4. Исходная картина

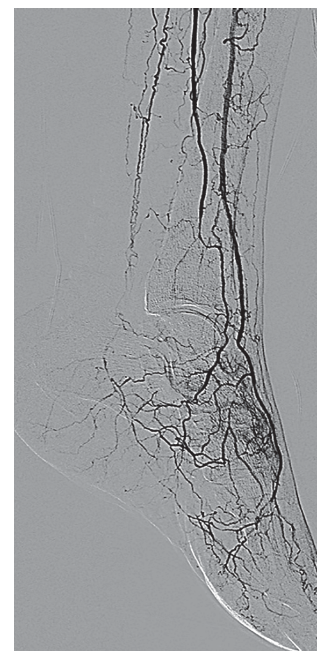


Fig. 5. Control angiography after TBA
Рис. 5. Контрольная ангиография после ТЛБА

over a period of 3 months. Seventeen patients underwent surgical treatment with a successful revascularization in only 12 (70.6%). Authors argued that this lower-than-expected success rate was due to a COVID-19-related hypercoagulable state [6]. They also reported that prolonged use of systemic heparin was associated with better outcomes in this subset of patients [6]. Perini and colleagues [7] reported 4 patients presenting with ALI caused by COVID-19. Two of their patients did not have any comorbidities, were relatively young, and receiving prophylactic doses of LMWH at presentation. One of them, a 53-year-old man, died on postoperative day 2 due

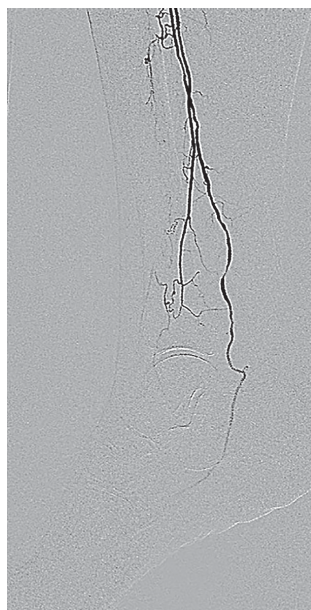

Fig. 6. Initial (before operation)
Рис. 6. Исходная картина

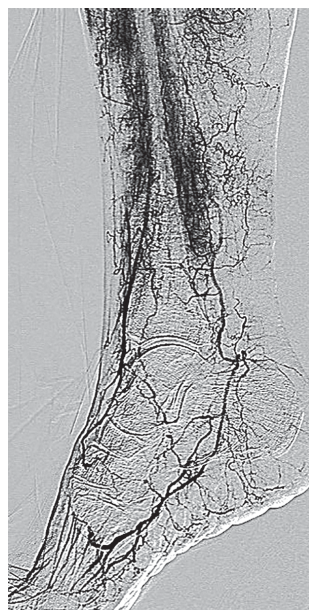


Fig. 7. Control angiography
after TBA
Рис. 7. Контрольная ангио-
графия после ТЛБА

to a recurrent aortoiliac occlusion. The other patient, a man aged 37 years with upper extremity thrombosis was successfully managed with UFH administration [7]. Baccellieri and colleagues [8] reported a patient who developed COVID-19-associated ALI while under prophylactic LMWH. The 67-year-old man with no relevant medical history was successfully treated with surgical intervention for simultaneous lower and upper limb ischemia [8].

Thromboembolic events associated with COVID-19 mainly manifest as VTE [5]. This is reasonable since COVID-19 exposes patients to all 3 components of Virchow's triad: (1) there is direct viral infection of endothelial cells [9]; (2) patients are frequently hospitalized and immobilized; (3) blood coagulation parameters are deranged representing a hypercoagulable state [3, 4]. Bilaloglu and colleagues [5] reported less than 1% incidence of ALI in their analysis of 3334 patients hospitalized with COVID-19. Of note, although not as frequent as VTE, incidence of ALI is increased during the COVID-19 pandemic [6].

Evidence from early experience suggests that pathogenesis of arterial thrombosis in COVID-19 patients differs from that of classical arterial thrombosis [10–16]. In-situ arterial thrombosis mainly occurs due to plaque breakdown or reduced perfusion through an atherosclerotic lesion, or stent or graft [14, 17, 18]. However, such as in the present case and others, COVID-19 patients may exhibit acute thrombosis of non-atherosclerotic native arteries [2]. Various mechanisms have been proposed to explain this phenomenon. A dysregulated hyperinflammatory response is thought to be responsible for arterial and venous thromboembolic events seen in patients with COVID-19 [11, 12, 19, 20]. Increased levels of D-dimer, fibrinogen, coagulation factors, acquired anti-phospholipid antibodies, and decreased levels of protein C, pro-

tein S, antithrombin, and hyperactivation of platelets and neutrophils are observed [10]. A consumption coagulopathy similar to sepsis-associated disseminated intravascular coagulopathy (DIC) is seen in COVID-19 patients. However, thrombotic component is more predominant than hemorrhagic component when compared with DIC [11, 12, 21]. It has been also speculated that direct viral infection of endothelial cells through the angiotensin-converting enzyme 2 receptor may be the cause of arterial thrombosis in patients with COVID-19 [9–11]. It is possible that a combination of these mechanisms, but not one, is responsible for increased rate of arterial thromboembolic events in COVID-19 patients.

CONCLUSION

COVID-19 infection is associated with an increased incidence of thromboembolic events, including ALI. Even young and otherwise healthy patients may develop ALI despite the use of prophylactic anticoagulation. SARS-CoV-2 infection is associated with a high thrombotic risk probably by promoting a systematic inflammatory response and a hypercoagulable state. COVID-associated ALI usually presents in patients with low number of comorbidities, and it is associated with a high mortality and amputation risk. Mortality risk seems to be greater with conservative treatment compared with any intervention, although the amputation risk is similar. Management of ALI in COVID-19 patients might be harder than expected, due to the hypercoagulable state. Patients may benefit from prolonged postoperative UFH administration.

Future studies should focus on identifying optimal medical treatment for these patients as well as potential prognostic factors for mortality and amputation risks.

ДОПОЛНИТЕЛЬНАЯ ИНФОРМАЦИЯ

Вклад авторов. Все авторы внесли существенный вклад в разработку концепции, проведение исследования и подготовку статьи, прочли и одобрили финальную версию перед публикацией.

Конфликт интересов. Авторы декларируют отсутствие явных и потенциальных конфликтов интересов, связанных с публикацией настоящей статьи.

Источник финансирования. Авторы заявляют об отсутствии внешнего финансирования при проведении исследования.

Информированное согласие на публикацию. Авторы получили письменное согласие пациентов на публикацию медицинских данных.

ADDITIONAL INFORMATION

Author contribution. Thereby, all authors made a substantial contribution to the conception of the study, acquisition, analysis, interpretation of data for the work, drafting and revising the article, final approval of the version to be published and agree to be accountable for all aspects of the study.

Competing interests. The authors declare that they have no competing interests.

Funding source. This study was not supported by any external sources of funding.

Consent for publication. Written consent was obtained from the patient for publication of relevant medical information within the manuscript.

ЛИТЕРАТУРА

1. Bjorck M., Earnshaw J.J., Acosta S. et al. J.C. Van Den Berg, Editor's choice-European society for vascular surgery (ESVS) 2020 clinical practice guidelines on the management of acute limb ischaemia, *Eur. J. Vasc. Endovasc. Surg.* 2020; 59(2): 173–218.
2. Gomez-Arbelaiz D., Ibarra-Sanchez G., Garcia-Gutierrez A. et al. COVID-19-related aortic thrombosis: a report of four cases, *Ann. Vasc. Surg.* 2020; 67: 10–3.
3. Han H., Yang L., Liu R. et al. Prominent changes in blood coagulation of patients with SARS-CoV-2 infection, *Clin. Chem. Lab. Med.* 2020; 58(7): 1116–20.
4. Tang N., Li D., Wang X., Sun Z. Abnormal coagulation parameters are associated with poor prognosis in patients with novel coronavirus pneumonia, *J. Thromb. Haemostasis.* 2020;18(4): 844–7.
5. Bilaloglu S., Aphinyanaphongs Y., Jones S. et al. Thrombosis in hospitalized patients with COVID-19 in a New York city Health system, *JAMA.* 2020; 324(8): 799–801.
6. Bellosto R., Luzzani L., Natalini G. et al. Acute limb ischemia in patients with COVID-19 pneumonia, *J. Vasc. Surg.* 2020. (article in press).
7. Perini P., Nabulsi B., Massoni C.B. et al. Acute limb ischaemia in two young, non-atherosclerotic patients with COVID-19, *Lancet.* 2020; 395(10236): 1546.
8. Baccellieri D., Bilman V., Apruzzi L. et al. A case of COVID-19 patient with acute limb ischemia and heparin resistance, *Ann. Vasc. Surg.* 2020; 68: 88–92.
9. Varga Z., Flammer A.J., Steiger P., Haberecker M. et al. Endothelial cell infection and endotheliitis in COVID-19, *Lancet.* 2020; 395(10234): 1417–8.
10. Piazza G., Morrow D.A. Diagnosis, management, and pathophysiology of arterial and venous thrombosis in COVID-19, *JAMA.* 2020; 324 (24): 2548–9.
11. Imdes J.E., Koleilat I., Hatch A.N. et al. Early experience with arterial thromboembolic complications in patients with COVID-19, *J. Vasc. Surg.* 2020. (article in press).
12. Shalhub S. The mystery of COVID-19-associated arterial thrombosis, *J. Vasc. Surg.* 2020. (article in press).
13. Obara H., Matsubara K., Kitagawa Y. Acute limb ischemia, *Ann. Vasc. Dis.* 2018; 11 (4): 443–7.
14. Kuchay A.A., Lipin A.N., Antropov A.V. et al. Treatment of multilevel lesions of arteries in lower extremities in cases of CLTI. Medical Alliance. 2022; 10(S3): 187–9. EDN IWSMIP.
15. Кучай А.А., Липин А.Н., Карелина Н.Р., Артюх Л.Ю. Реваскуляризация нижней конечности на основе концепции ангиосомы с ранней локальной реконструкцией лоскута (клинический случай). *Forcipe.* 2022; 5(4): 29–35.
16. Кучай А.А., Липин А.Н., Карелина Н.Р. и др. Реваскуляризация при протяженных окклюзиях поверхностной части бедренной артерии и многоэтажных поражениях артерий нижней конечности. *Forcipe.* 2022; 5(3): 4–14.
17. Кучай А.А., Липин А.Н., Антропов А.В. и др. Гибридный подход в лечении протяженных окклюзий артерий нижних конечностей при КИНК. *Ангиология и сосудистая хирургия.* 2019; 25(2): 260–264.
18. Кучай А.А., Липин А.Н., Антропов А.В. и др. Лечение многоэтажных поражений артерий нижних конечностей при КИНК. *Ангиология и сосудистая хирургия.* 2021; 27(2): 410–412.
19. Кучай А.А., Липин А.Н., Антропов А.В. и др. Концепция «ДИСТАЛЬНОГО ГИБРИДА» при протяженных окклюзиях поверхностной бедренной артерии с тяжелым поражением путей оттока при критической ишемии нижних конечности. *Ангиология и сосудистая хирургия.* 2022; 28(S1): 157–161.
20. Кучай А.А., Липин А.Н., Антропов А.В. и др. Гибридный подход к протяженным окклюзиям ПБА при КИНК. *Ангиология и сосудистая хирургия.* 2022; 28 (S1): 161–163.
21. Курьянов П., Липин А., Антропов А. и др. Ангиопластика подколенной артерии при хронических тотальных окклюзиях с дистальной посадочной зоной и без нее. *Annals of vascular surgery;* 2020; 62 (68): 417–425.

REFERENCES

1. Bjorck M., Earnshaw J.J., Acosta S. et al. J.C. Van Den Berg, Editor's choice-European society for vascular surgery (ESVS) 2020 clinical practice guidelines on the management of acute limb ischaemia, *Eur. J. Vasc. Endovasc. Surg.* 2020; 59(2): 173–218.
2. Gomez-Arbelaiz D., Ibarra-Sanchez G., Garcia-Gutierrez A. et al. COVID-19-related aortic thrombosis: a report of four cases, *Ann. Vasc. Surg.* 2020; 67: 10–3.
3. Han H., Yang L., Liu R. et al. Prominent changes in blood coagulation of patients with SARS-CoV-2 infection, *Clin. Chem. Lab. Med.* 2020; 58(7): 1116–20.
4. Tang N., Li D., Wang X., Sun Z. Abnormal coagulation parameters are associated with poor prognosis in patients with novel coronavirus pneumonia, *J. Thromb. Haemostasis.* 2020;18(4): 844–7.
5. Bilaloglu S., Aphinyanaphongs Y., Jones S. et al. Thrombosis in hospitalized patients with COVID-19 in a New York city Health system, *JAMA.* 2020; 324(8): 799–801.
6. Bellosto R., Luzzani L., Natalini G. et al. Acute limb ischemia in patients with COVID-19 pneumonia, *J. Vasc. Surg.* 2020. (article in press).
7. Perini P., Nabulsi B., Massoni C.B. et al. Acute limb ischaemia in two young, non-atherosclerotic patients with COVID-19, *Lancet.* 2020; 395(10236): 1546.
8. Baccellieri D., Bilman V., Apruzzi L. et al. A case of COVID-19 patient with acute limb ischemia and heparin resistance, *Ann. Vasc. Surg.* 2020; 68: 88–92.
9. Varga Z., Flammer A.J., Steiger P., Haberecker M. et al. Endothelial cell infection and endotheliitis in COVID-19, *Lancet.* 2020; 395(10234): 1417–8.



10. Piazza G., Morrow D.A. Diagnosis, management, and pathophysiology of arterial and venous thrombosis in COVID-19, *JAMA*. 2020; 324 (24): 2548–9.
11. Imdes J.E., Koleilat I., Hatch A.N. et al. Early experience with arterial thromboembolic complications in patients with COVID-19, *J. Vasc. Surg.* 2020. (article in press).
12. Shalhub S. The mystery of COVID-19-associated arterial thrombosis, *J. Vasc. Surg.* 2020. (article in press).
13. Obara H., Matsubara K., Kitagawa Y. Acute limb ischemia, *Ann. Vasc. Dis.* 2018; 11 (4): 443–7.
14. Kuchay A.A., Lipin A.N., Antropov A.V. et al. Treatment of multilevel lesions of arteries in lower extremities in cases of CLTI. *Medical Alliance*. 2022; 10(S3): 187–9. EDN IWSMIP.
15. Kuchay A.A., Lipin A.N., Karelina N.R., Artyukh L.Yu. Revascularization of lower limb based on the angiosome concept with early local flap reconstruction (A CASE REPORT). *Forcipe*. 2022; 5(4): 29–35.
16. Kuchay A.A., Lipin A.N., Karelina N.R. et al. Revascularization in extended occlusions of the superficial part of the femoral artery and multi-storey lesions of the arteries of the lower extremity. *Forcipe*. 2022; 5(3): 4–14.
17. Kuchay A.A., Lipin A. N., Antropov A.V. et al. Hybrid approach in treatment of extended occlusive arteries of the lower extremities in CLTI. *Angiology and vascular surgery*; 2019; 25(S2): 260–4.
18. Kuchay A.A., Lipin A. N., Antropov A.V. et al. Treatment for multi-storey lesions of lower extremities in CLTI. *Angiology and vascular surgery*; 2021; 27(S2): 410–2.
19. Kuchay A.A., Lipin A. N., Antropov A.V. et al. Concept of a «DISTAL HYBRID» for long occlusions of the superficial femoral artery with severe damage to the outflow pathways at critical ischemia of the lower extremity. *Angiology and vascular surgery*. 2022; 28(S1): 157–61.
20. Kuchay A.A., Lipin A. N., Antropov A.V. et al. Hybrid approach to long occlusion of SFA with CLTI. *Angiology and vascular surgery*. 2022; 28(S1): 161–3.
21. Kurianov P., Lipin A., Antropov A. et al. Popliteal artery angioplasty for chronic total occlusions with versus without the distal landing zone. *Annals of vascular surgery*; 2020; 62(68): 417–25.

