

DOI: 10.56871/RBR.2024.68.81.005

УДК 612.13+616-005.4-089.819.5+616-031.37/.38+617.58+616.137.8/.9-008.64

КРИТИЧЕСКАЯ ИШЕМИЯ НИЖНИХ КОНЕЧНОСТЕЙ И ЕЕ ЛЕЧЕНИЕ

© Аршед Ахмад Кучай^{1, 3}, Александр Николаевич Липин^{2, 3}, Никита Николаевич Груздев³, Алексей Геннадьевич Борисов³, Ильяс Салаватович Кашапов⁴

¹ Клиника Мед2. 191036, Российская Федерация, г. Санкт-Петербург, ул. Восстания, 11

² Военно-медицинская академия им. С.М. Кирова. 194044, Российская Федерация, г. Санкт-Петербург, ул. Академика Лебедева, 6

³ Городская больница № 14. 198099, Российская Федерация, г. Санкт-Петербург, ул. Косинова, 19/9

⁴ СПб ГБУЗ «Городская поликлиника № 120». 195426, Российская Федерация, г. Санкт-Петербург, ул. Ленская, 4/1

Контактная информация: Аршед Ахмад Кучай — врач сердечно-сосудистый хирург, клинический исследователь
Городского центра спасения конечностей. E-mail: drarshedcvs@gmail.com ORCID: <https://orcid.org/0000-0002-7974-9369> SPIN: 5455-9033

Для цитирования: Кучай А.А., Липин А.Н., Груздев Н.Н., Борисов А.Г., Кашапов И.С. Критическая ишемия нижних конечностей и ее лечение // Российские биомедицинские исследования. 2024. Т. 9. № 1. С. 34–47. DOI: <https://doi.org/10.56871/RBR.2024.68.81.005>

Поступила: 04.12.2023

Одобрена: 11.01.2024

Принята к печати: 04.03.2024

Резюме. Критическая ишемия, угрожающая конечностям, — наиболее распространенная форма заболевания периферических артерий, которая связана со значительной заболеваемостью, смертностью и использованием ресурсов здравоохранения. Это клинический синдром ишемической боли в покое или потери тканей, например незаживающих язв или гангрены, связанный с заболеванием периферических артерий. Хроническая ишемия угрожающей потери конечности (ХИУПК) имеет высокий краткосрочный риск потери конечностей и сердечно-сосудистых событий. Неинвазивная или инвазивная ангиография помогает определить возможность и подход к артериальной реваскуляризации. Часто предлагается подход «сначала эндоваскулярный», основанный на более низком риске процедуры, однако при определенных формах заболевания лучше всего лечить открытую хирургическую реваскуляризацию. Баллонная ангиопластика и стентирование составляют основу эндоваскулярных методов, при этом стенты с лекарственным покрытием и баллоны с лекарственным покрытием обеспечивают низкую вероятность повторной реваскуляризации. Комбинация антеградного и ретроградного подходов может повысить успех при протяженной тотальной окклюзии. Ангиопластика ниже колена, направленная на ангиосомы, может привести к более быстрому заживлению ран, но если это не удалось, то сохраняется любой прямой поток крови в стопу. Гибридные хирургические методы, такие как стентирование подвздошной артерии и бедренная эндартерэктомия, обычно используются для снижения операционного риска. Шунтирование нижних конечностей наиболее эффективно при использовании длинной одностебельной аутогенной вены хорошего качества диаметром не менее 3,5 мм. Небольшие ампутации часто требуются из-за потери тканей в рамках стратегии лечения. Большие ампутации (на уровне лодыжки или выше) ограничивают функциональную независимость, и их предотвращение является ключевой целью терапии критической ишемии нижних конечностей (КИНК)/ХИУПК. Медикаментозная терапия после реваскуляризации нацелена на факторы риска атеросклероза и оценивает заживление ран и новые или рецидивирующие заболевания, ограничивающие кровоток.

Ключевые слова: заболевания периферических артерий, эндоваскулярные вмешательства, сосудистые вмешательства, сосудистые заболевания конечностей, сосудистая хирургия, критическая ишемия, угрожающая конечности, баллоны с лекарственным покрытием, стент с лекарственным покрытием

CRITICAL LIMB THREATENING ISCHEMIA AND ITS MANAGEMENT

© Arshed A. Kuchay^{1, 3}, Alexander N. Lipin^{2, 3}, Nikita N. Gruzdev³, Aleksey G. Borisov³, Ilyas S. Kashapov⁴

¹ Med2 clinic. Vosstaniya str., 11, Saint Petersburg, Russian Federation, 191036

² Military Medical Academy named after S.M. Kirov. Akademichan Lebedev str., 6, Saint Petersburg, Russian Federation, 194044

³ Limb Salvage Center, City Hospital № 14. Kosinova str., 19/9, Saint Petersburg, Russian Federation, 198099

⁴ Saint Petersburg City Polyclinic No. 120. Lenskaya str., 4/1, Saint Petersburg, Russian Federation, 195426

Contact information: Arshed A. Kuchay — cardiovascular surgeon, clinical researcher of the City Limb Salvage Center.
E-mail: drarshedcvs@gmail.com ORCID: <https://orcid.org/0000-0002-7974-9369> SPIN: 5455-9033



teria range from less than 40–70 mmHg, toe pressures less than 30–50 mmHg, TcO_2 less than 20–40 mmHg. Higher cut points are often used for tissue loss on the assumption that greater perfusion is required for wound healing, but expert consensus on these hemodynamic criteria differs between guidelines [2, 4–7]. The original definitions were designed to standardize entry criteria for clinical trials of CLTI in patients without diabetes to permit comparisons across studies [4, 6] or to assess the likelihood of wound healing [8]. However, their value as diagnostic tests of CLTI in clinical practice are more controversial [2, 5, 9]. Defining specific cut points of toe pressure or TcO_2 for the clinical diagnosis of CLTI is difficult because of the considerable overlap in values among CLTI patients who do or do not progress to major amputation or cardiovascular events (Figure 1) [10, 11]. One trial suggests they don't impact the decision for revascularization [12]. Other definitions of

CLTI incorporate wound infection and osteomyelitis in addition to ischemia [13].

For clinical purposes rest pain or non-healing wounds may suffice as a definition to justify the use of expensive technology (angiography and revascularization) which are fundamental to the clinical treatment of this condition.

NATURAL HISTORY OF CLTI

Patient outcomes in critical limb ischemia are largely determined by morbidity and mortality due to cardiovascular events and functional impairment due to limb loss. Although, over the whole spectrum of PAD, cardiovascular events such as myocardial infarction and stroke occur in 30–50% of subjects over a 5 year period, patients with CLI face this risk over a one year period [1, 2, 14] — an outcome worse than many cancers or severe heart failure. Similarly, although the risk of major amputation (at or above the ankle) is less than 5% over 5–10 years in patients with claudication, it is at least 30–50% in the first year in patients with CLI who do not have revascularization [2].

ASSESSMENT AND INITIAL TREATMENT

The clinical presentation of CLI depends on the degree of ischemia, the presence of infection, and co-existing neuropathy [1]. Ischemic pain is usually worse when the patient is supine and often requires narcotics for analgesia. It may waken patients from sleep and prevent them from walking. Infection can increase pain even without severe ischemia. Neuropathy can contribute to tissue injury or mask pain from an ulcer.

Current guidelines recommend measuring the ankle pressure or ankle brachial index [1, 2, 5], although medial calcinosis may yield artificially high values in which case toe pressures may indicate arterial obstruction. TcO_2 or skin perfusion pressures may indicate the likelihood of wound healing.

The primary goal is to preserve limb function. Revascularization is a fundamental strategy to limb preservation, but in some patients, this does not improve limb function and mobility. For example, cognitive impairment, non-ambulatory status prior to CLI, and severe comorbidities portend a poor prognosis even with revascularization [15]. When revascularization is considered, arterial imaging identifies the targets and mode of revascularization.

Duplex ultrasound, and non-invasive angiography with computerized tomography (CTA) or magnetic resonance (MRA), can demonstrate arterial obstruction. Duplex ultrasound does not require contrast but requires specific training and may not image the tibial arteries very easily. In infra-inguinal disease, vein mapping is required to determine the feasibility of surgical bypass with autogenous vein.

CTA requires iodinated contrast and may cause contrast nephropathy in patients with impaired renal function. Heavily arterial calcification can create artefacts that limit CTA particularly in distal disease. Non-contrast time-of-flight MRA is prone to artifact with non-laminar flow typical of atherosclerotic plaque, and con-

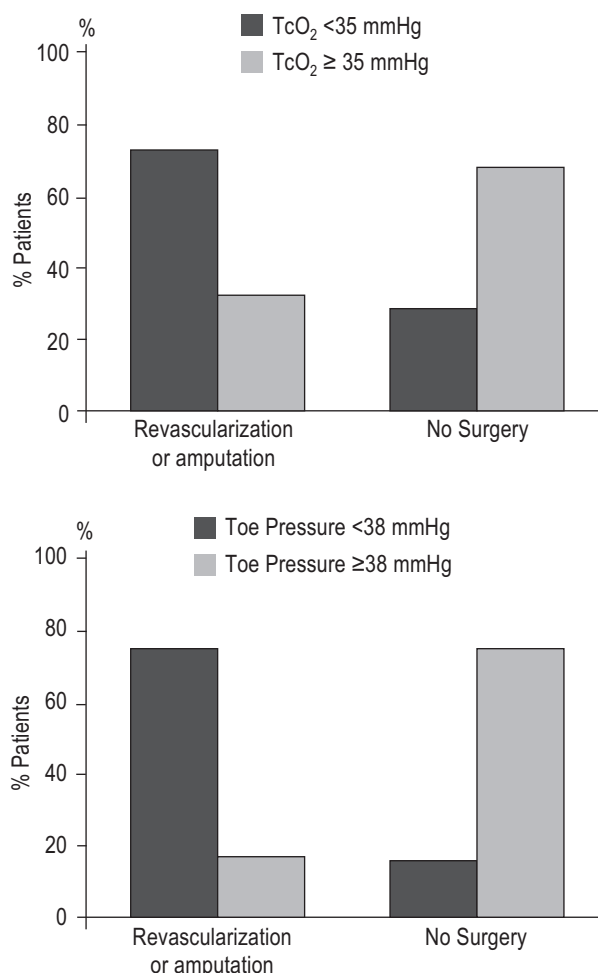


Рис. 1. Результаты перекрытия TcO_2 и давления на палец стопы у пациентов, нуждающихся в ревазуляризации или ампутации по поводу КИНК, и у пациентов, получающих медикаментозное лечение (по данным Уббинка и др. [11])

Fig. 1. Overlap in TcO_2 and toe pressure results between patients requiring revascularization or amputation for CLI and patients managed medically (from data in Ubbink et al. [11])

cerns of nephrogenic systemic fibrosis from gadolinium contrast limit its use in advanced kidney disease [16]. CTA and MRA are sometimes inadequate to assess the smaller tibial arteries. Nevertheless, CTA and MRA can help localize disease targets and help plan the mode and approach to revascularization.

Due to limitations in imaging distal arteries non-invasively, invasive angiography is often used to clarify the potential for revascularization and should be considered prior to major amputation. Invasive angiography uses iodinated contrast and provides the highest spatial resolution. Diagnostic cases can use as little as 30 mL of contrast for both legs with conventional and digital subtraction angiography.

Initial treatments include control of pain, which may require narcotics, pressure relief of ulcers, sheepskin boots to increase superficial collateral supply, and tilting the bed downward to increase limb dependency and perfusion [2]. Pain relief may reverse sympathetic-mediated vasoconstriction. Although some of these measures only marginally improve perfusion, they may reduce the discomfort associated with CLI while planning definitive treatment.

ENDOVASCULAR REVASCULARIZATION

In many centers, endovascular revascularization is the favored approach to CLI, because of lower morbidity and mortality compared to open surgery (Figure 2). The optimal treatment strategy (endovascular versus open surgery) will depend on anatomical factors, comorbidities, patient preference and operator experience and skill. Although claudication can be relieved by inflow revascularization (aorto-iliac and femoral), CLI is often associated with multilevel disease and usually requires outflow (tibial) revascularization as well as treating inflow disease. Much of the evidence for endovascular treatment of inflow disease is based on studies of patients with claudication or a mix of claudication and CLI [52].

INFLOW AND FEMORAL-POPLITEAL DISEASE

Aorto-iliac disease can be approached from the ipsilateral or contralateral common femoral arteries, or brachial and radial arteries. Rarely a retrograde approach from the popliteal artery can assist crossing superficial femoral artery occlusions which cannot be traversed antegrade [3] (Figure 3). The retrograde popliteal approach requires access from above from the contralateral or antegrade common femoral artery, then turning the patient prone on the table and using ultrasound with a micro puncture needle to access the popliteal artery at or just above the knee joint. Small sheaths (4–5 French) provide access for a wire which can be snared from above once it traverses the occlusion. A wire that is exteriorized above and below and occlusion provides a rigid rail to assist pushing catheters and balloons through an occlusion (the “dental floss” technique).

A variety of systems are used to cross lesions including 0.035", 0.025", 0.018", and 0.014" diameter wires and balloons. Concerns of recoil of ostial lesions and dissections associated with occluded or calcified disease has led to the almost universal practice of primary stenting in iliac disease [17]. Balloon expandable stents offer greater radial force and a more precise deployment (especially useful in ostial locations), whereas nitinol self-expanding stents may be useful in long tapered lesions. Covered stents are useful for life-threatening perforations of the iliac artery during endovascular treatment. Their value in preventing restenosis is uncertain [3], due to concerns of increased rates of stent thrombosis and the potential to jail and occlude branch vessels.

Common femoral disease often involves the profunda and SFA origins. Endovascular treatment alone can achieve durable results with acute dissection of the common femoral artery from arterial closure devices. Stents are avoided in this region due to the repeated flexion and extension of this artery and potential for stent fracture, as well as jailing the profunda artery – an important collateral in the event of SFA occlusion [84–86, 91–93]. Preserva-

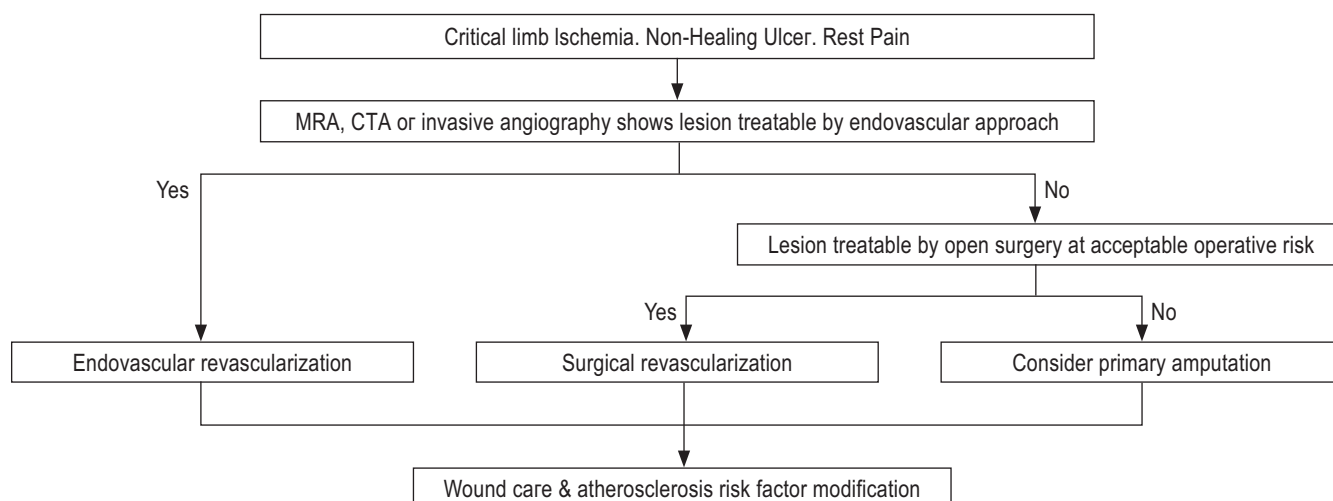


Рис. 2. Алгоритм подхода к реваскуляризации у больных с критической ишемией конечностей

Fig. 2. Algorithm for the approach to revascularization in patients with critical limb ischemia

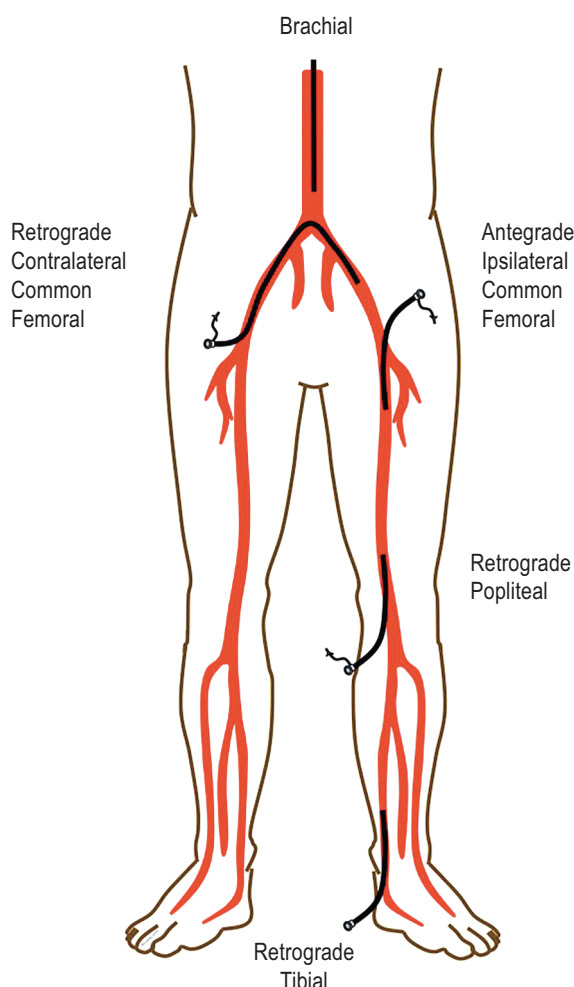


Рис. 3. Подход к артериальному доступу при эндоваскулярной реваскуляризации нижних конечностей

Fig. 3. Approach for arterial access for endovascular revascularization of the lower limbs

tion of both branches with balloon angioplasty alone can be difficult with complex calcified plaques, and often surgical endarterectomy with patch angioplasty offers a more durable result. Hybrid endovascular-surgical approaches using endovascular approaches for iliac or superficial femoral disease and endarterectomy for common femoral disease are increasingly used [18]. New developments in atherectomy and drug coated balloons have renewed interest in endovascular approaches for common femoral disease, although this paradigm needs formal testing in clinical trials.

The SFA is the longest artery in the leg and subject to flexion, compression and torsion. These forces are particularly important close to the knee and the common femoral artery. Balloon angioplasty offers similar results to stenting in short lesions (<100 mm) when there is good arterial expansion without flow limiting dissections [19]. Minor dissections often heal without long-term sequelae. Nitinol self-expanding stents offer better long-term patency in longer lesions [20] and re-expand after external radial compression. Stent fracture is thought to increase in-stent restenosis, but is

much rarer with the newer self-expanding stent platforms [20–23]. Recent drug-eluting stents designs offer a lower rate of restenosis compared to bare-metal self-expanding stents [24].

Drug-coated balloons offer lower rates of restenosis than balloon angioplasty alone in patients with SFA disease and claudication [25–27]. Drug-coated balloons also prevent restenosis when used prior to bare-metal stent deployment [28], and offer more durable treatment of in-stent restenosis of the femoral artery [29]. The evidence supporting drug-eluting stents and drug-coated balloons is much stronger than for covered-self expanding stents, which have uncertain effects on restenosis and stent thrombosis [30].

Chronic total occlusions of the SFA are common in symptomatic PAD [87–90]. A variety of techniques and devices for crossing total occlusions and re-entering the true lumen in the distal artery are available, but few have been tested in randomized trials. These include hydrophilic wires to dissect through the intima or the medial (“subintimal”) layers of the artery. Specialty catheters include those with dissection devices, vibrational energy, drilling heads, and laser capabilities to penetrate the fibrous cap and length of occluded plaque. Intravascular ultrasound can confirm an intraluminal location of a wire in an occlusion (Figure 4), and other devices to redirect a 0.014" wire from a dissection plane into the distal true lumen can facilitate crossing femoral artery occlusions. A number of atherectomy devices are also available to debulk lesions and may have utility in niche areas such as heavily calcified lesions resistant to balloon and stent dilation [3]. However, a meta-analysis suggested no clear benefit from using atherectomy devices alone compared to balloon angioplasty [31]. Recent interest in the use of atherectomy combined with drug-coated balloons requires further testing, particularly in areas where stents are avoided (over the knee and hip joints). Given the high risks of major amputation, stenting over the knee joint is sometimes required to maintain patency. A number of specialty stents with greater durability to repeated flexion are designed for the popliteal artery in particular [23].

TIBIAL DISEASE

There is rarely a justification for tibial interventions in claudication. However, wound healing and relief of CLTI is more dependent on establishing straight-line flow into the foot. Therefore below-knee popliteal and tibial artery interventions are more commonly pursued in CLTI.

Access is more limited for distal tibial disease as a contralateral common femoral approach or brachial approach are often too distant for most equipment based on 130–150 mm shaft lengths. An antegrade femoral approach also gives more “pushability” to drive through long occlusions. The retrograde tibial approach can be used for tibial and popliteal occlusions which cannot be crossed antegrade (Figure 3), but if unsuccessful may create a non-healing ulcer at the access site. The retrograde pedal or tibial artery approach uses ultrasound and a micropuncture needle for access and the dilator of the micropuncture kit or a small sheath for wire access. Access from above (e.g. antegrade

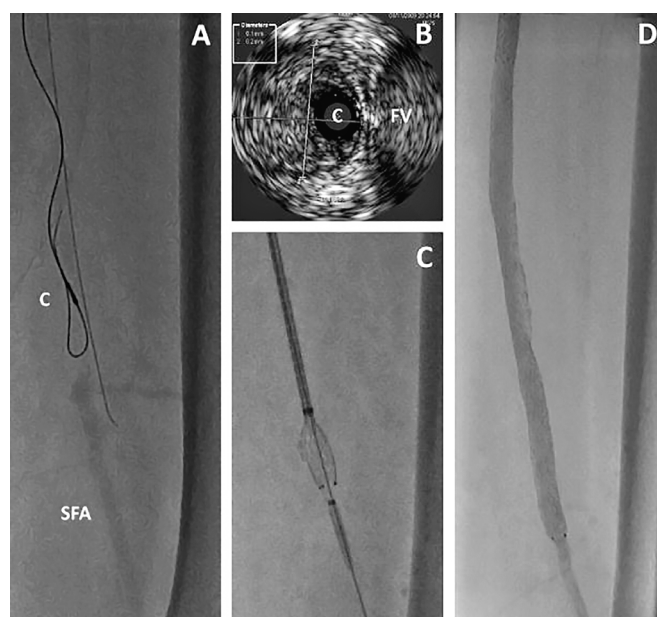


Рис. 4. Внутрисосудистое ультразвуковое исследование (ВСУЗИ) используется для оценки внутриартериального расположения при прохождении длительной окклюзии: А — катетер ВСУЗИ (С) виден через петлеобразную проволоку в окклюзированном сегменте средней поверхностной бедренной артерии. Прилегающий провод является внеартериальным. Поверхностная бедренная артерия (ПБА) указывает на дистальную поверхностную бедренную артерию за пределами окклюзии; В — изображение ВСУЗИ, показывающее катетер (С) в середине артерии, рядом с бедренной веной (БВ). Диаметр артерии составлял 6,1×6,2 мм, что соответствует среде и интима и, вероятно, превышает эталонный диаметр просвета; С — раскрытие стента после успешного пересечения окклюзированной артерии; D — окончательный результат ангиографии

Fig. 4. Intravascular ultrasound (IVUS) used to assess the intra-arterial location while traversing a long occlusion: A — the IVUS catheter (C) is seen over a looped wire in an occluded segment of the mid superficial femoral artery. An adjacent wire is extra-arterial. SFA indicates the distal superficial femoral artery beyond the occlusion; B — IVUS image showing the catheter (C) in the middle of the artery and adjacent to the femoral vein (FV). The diameter of the artery was 6.1×6.2 mm, which represents to media and intima and likely overestimates the reference lumen diameter; C — stent deployment after successfully traversing the occluded artery; D — final result on angiography

femoral) allows a retrograde wire to be snared and exteriorized above and below the tibial or popliteal occlusion to provide a rigid rail to drive catheters and balloons through an occlusion (Figure 5, 6, 7).

The value of angiosome directed revascularization versus restoring any straight-line flow into the foot is debated. The former assumes that revascularization of a tibial artery supplying the angiosome of the ulcer or gangrenous region (Figure 8) is more likely to promote healing than non-angiosome revascularization

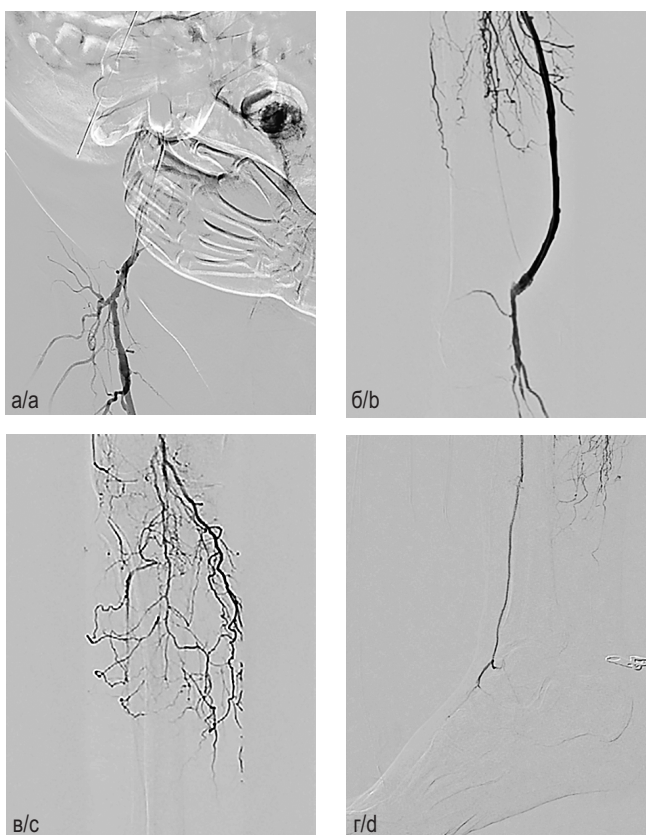


Рис. 5. Антеградный бедренный доступ через общую бедренную артерию (ОБА) справа. Интраоперационная ангиография: а — ОБА, глубокая бедренная артерия (ГБА), проксимальный анастомоз глубоко бедренно-подколенное шунтирование (ГБПШ); б — ГБПШ, дистальный анастомоз; в — слепой сегмент подколенной артерии (ПКА); г — передняя большеберцовая артерия (ПБА), окклюзия артерий голени

Fig. 5. Antegrade femoral approach through CFA on the right side. Intraoperative angiography: a — CFA, DFA, proximal anastomosis DfPB; b — DfPB, distal anastomosis; c — blind segment of PopA; d — ATA, occlusion of the arteries of the leg

which relies on increased collateral flow to an ischemic region. In observational studies, wound healing was greater and amputation lower with angiosome-directed compared to indirect (non-angiosome) tibial revascularization [32]. However, these observations may be confounded. Indirect revascularization, may be a marker for more complex tibial disease, which may be associated both with no option for angiosome directed revascularization and poorer limb salvage. In one study, changes in foot microcirculation assessed by skin perfusion pressure improved regardless of whether the angiosome related tibial artery or the non-angiosome related artery was revascularized [33]. Although it makes intuitive sense to use an angiosome directed treatment wherever possible, if this is not successful, any straight-line flow should be better than none.

Primary balloon angioplasty of tibial disease provides a good response in most situations. Long balloons are specifically

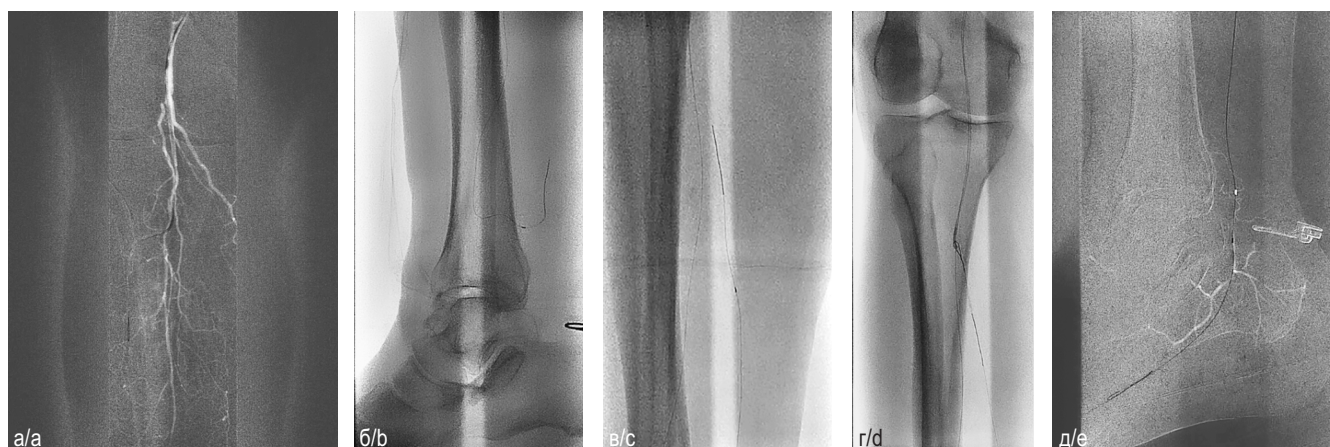

Рис. 6. Этапы операции: а — реканализация передней большеберцовой артерии с использованием модифицированного катетера; б — трансколлатеральная реканализация задней большеберцовой артерии через коммуникантную ветвь малой берцовой артерии; в — ретроградная реканализация задней большеберцовой артерии; г — реканализация истока задней большеберцовой артерии встречными проводниками при поддержке модифицированного катетера; д — реканализация латеральной плантарной артерии

Fig. 6. Stages of the operation: a — recanalization of the anterior tibial artery using a modified catheter; б — transcollateral recanalization of the posterior tibial artery through the communicating branch of the small tibial artery; в — retrograde recanalization of the posterior tibial artery; г — recanalization of the origin of the posterior tibial artery with counter conductors supported by a modified catheter; д — recanalization of the lateral plantar artery

designed to treat the often diffuse tibial disease with prolonged inflations. Stents are reserved for poor balloon results (re-occlusion, recoil to more than 50% stenosis, flow-limiting dissection). Tibial arteries are about 2.5–3.5 mm in diameter, and are usually treated with balloon expandable coronary stents with a spot-stenting philosophy. Proximal lesions are somewhat protected by the bulk of the calf muscle, but can theoretically be crushed by external compression. Stent crush is more likely with extensive stenting and stents in the distal calf. Poor outflow theoretically increases the risk of stent thrombosis and may reduce the enthusiasm for stenting. Randomized studies in tibial arteries show better patency and less need for reintervention with drug-eluting compared to bare-metal coronary stents [34–36], with one trial showing lower rates of amputation [35].

Compared to conventional balloon angioplasty, drug-coated balloons for tibial interventions provided promising results in early series and single center trials [37]. However, restenosis rates were higher than drug-eluting stents in one small trial [38], and the multicenter randomized IN.PACT DEEP study raised concerns because of a trend to more amputations in the drug-coated versus standard balloon angioplasty arms (8.8% versus 3.6%, $p=0.08$) [39]. Reasons for the lackluster results compared to femoral-popliteal disease include reduced drug delivery due to drug coating after balloon wrapping and poor drug-release characteristics. Further randomized trials will explore their value in tibial arteries.

Atherectomy in tibial arteries is of uncertain value beyond balloon angioplasty and stenting [31]. Long segment tibial atherectomy could cause embolization which decreases outflow and distal perfusion. One recent report showed greater acute success, but no difference in amputation, repeat revas-

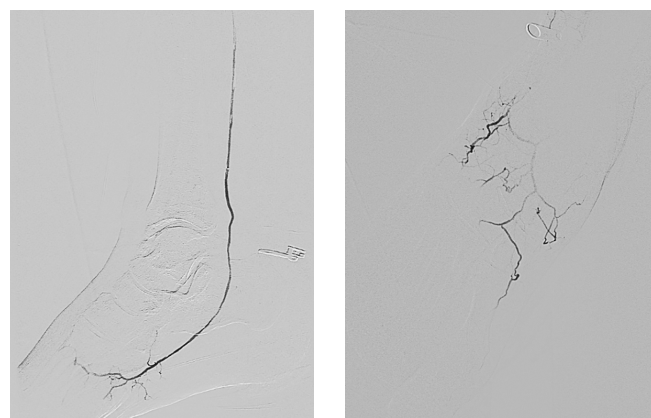


Рис. 7. Контрольная ангиография — прямая реваскуляризация стопы и трофических дефектов

Fig. 7. Control angiography — direct revascularization of the foot and trophic defects

cularization or mortality with laser assisted versus conventional angioplasty [40].

Wire perforation of the tibial arteries is usually easily treatable by low-pressure balloon angioplasty, but larger perforations may require longer balloon inflations or covered stents to avoid a compartment syndrome which can cause ischemic muscle and nerve injury and threaten the viability of the lower limb.

OPEN SURGICAL REVASCULARIZATION

The goals of surgical revascularization are to provide straight-line flow into the foot, promote wound healing, and to limit the level

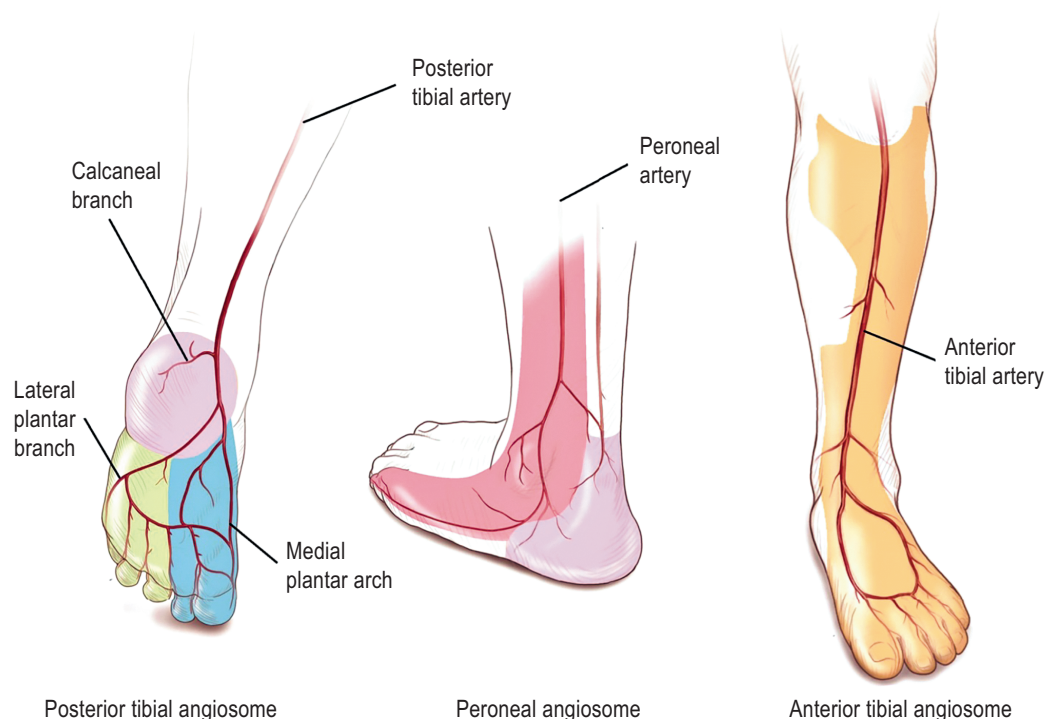


Рис. 8. Ангиосомы нижней конечности ниже колена

Fig. 8. Angiosomes of the below-the-knee lower extremity

of amputation. Open surgery has higher risks of peri-operative myocardial infarction, death and stroke than endovascular revascularization. However, in critical limb ischemia, the potential loss of limb and function may favor surgery when endovascular therapy is not possible or not successful and patients otherwise have a reasonable 2 year survival [18]. Risk scores can help risk-stratify CLTI patients having infrainguinal bypass surgery. For example, the PREVENT III risk score includes dialysis, tissue loss, age ≥ 75 years, and coronary artery disease [41]. A higher score associates with a lower risk of survival free from amputation. In addition to patient risk, assessment includes vein mapping of saphenous vein to determine available autogenous conduit. This is particularly important in patients who may have had vein harvested for coronary artery bypass in the past.

Multilevel disease is often treated with hybrid revascularization using endovascular techniques to treat inflow disease (e.g., iliac stenting), and surgical revascularization for femoral or infrainguinal disease (Figure 4) (e.g., common femoral endarterectomy, and femoral popliteal bypass) [18]. Rarely, occlusion of the distal aorta and iliac disease may require aorto-bifemoral bypass, contralateral femoral to femoral bypass [84–93], or axillary-femoral bypass [18] (Figure 5, 6, 7).

Common femoral endarterectomy may extend into the proximal SFA or profunda artery. Closure is usually achieved with a bovine or synthetic patch to reduce restenosis, or sometimes with primary closure without a patch [18]. Complications include wound infection (particularly in obese patients), hematoma and lymph leak. This procedure offers a high long-term patency rate ($>90\%$) and considered superior to endovascular treatment par-

ticularly for heavily calcified disease involving the SFA and profunda origins.

As with endovascular treatment, infrainguinal bypass relies on good inflow and outflow. The three types of saphenous vein bypass are reversed (translocated) vein, nonreversed vein, and in situ bypass where vein branches are ligated and the distal ends mobilized and anastomosed to the artery. The latter two configurations require excision of the valves with a valvulotome, which can sometimes injure the vein conduit. Observational studies suggest similar outcomes with all three configurations [18, 42]. Limb salvage and graft patency are best with good quality, long, single-segment, autogenous vein with a diameter of at least 3.5 mm [43–45]. In the PREVENT III trial, bypass grafts with these characteristics had a low 30day failure rate (less than 2%), and high secondary patency and limb salvage at one year (approximately 90%) [45].

In pooled analyses, autogenous saphenous vein provided better long-term patency than prosthetic grafts for above- and below-knee grafts [44, 46, 47]. Prosthetic grafts of heparin-bonded polytetrafluoroethylene may provide better outcomes than older prosthetic grafts [48] with comparable results to autologous vein in a one retrospective study [49]. Cryopreserved cadaveric vein has poorer long-term patency results [50].

AMPUTATION

Minor amputations such toe, ray (toe and metatarsal), or transtatarsal amputations require an adequate blood supply into the foot to maximize healing and are usually part of the treat-

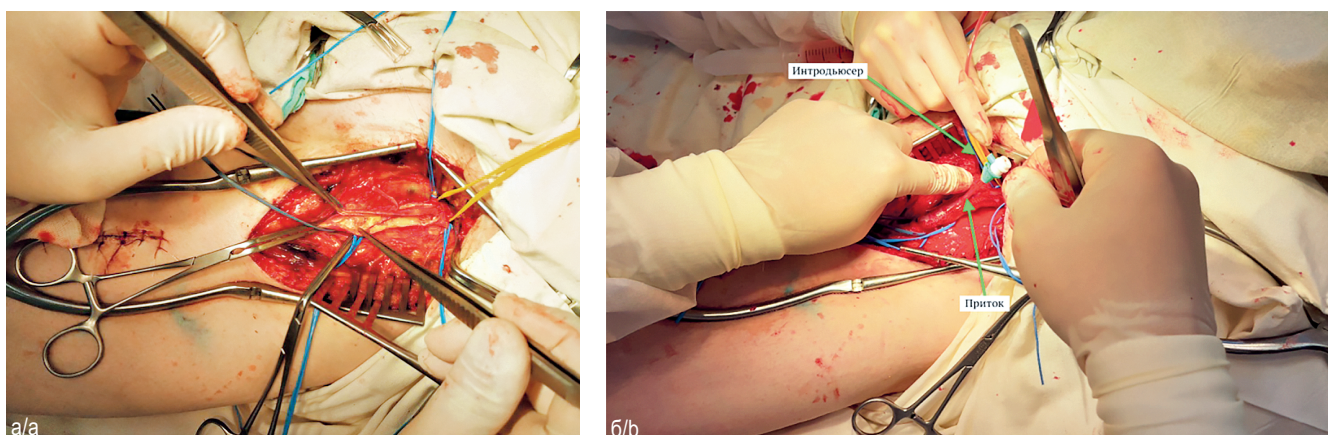


Рис. 9. Эндартерэктомия из ОБА слева с пластикой аутовенозной заплатой (а); заведение интродьюсера в приток аутовенозной заплаты (б). Выполнена открытая эндартерэктомия из общей бедренной артерии с пластикой аутовенозной заплатой. При выделении аутовенозного кондукта сохранен крупный приток, заведен интродьюсер

Fig. 9. Endarterectomy from the CFA on the left side repair with an autovenous patch (a); insertion of the introducer/sheath into the inflow of the autovenous patch (b). An open endarterectomy was performed from the common femoral artery with autovenous patch repair. When the autovenous conduit is isolated, a large inflow is preserved, and an introducer is inserted

ment plan for gangrene or tissue loss after successful revascularization. Generally, minor amputation does not limit functional independence or require a prosthesis.

Major amputations (at or above the knee) limit functional independence and require a prosthesis to walk. Although preventing major amputation is a key goal, amputation may be indicated for failed revascularization, patients with extensive tissue loss or infection, patients unfit for surgical revascularization with no endovascular options, and potentially non-ambulating patients. Up to one third of below-knee amputations may require further surgery or an above-knee amputation due to poor healing [53]. A patent popliteal pulse reduces the failure rate of healing to less than 10%. More than 90% of above-knee amputations heal, but only about 20% of amputees regain full mobility with a prosthesis compared to 60% with a below-knee prosthesis [53, 54]. Factors related to poor prosthesis use and function after major amputation include increasing age, bilateral or above-knee amputations, dementia, and poor function prior to amputation [54].

WOUND CARE

Wound care principles include improving perfusion into the limb, treating infection, avoiding pressure on a wound, debridement, and adequate nutrition (Figure 9, 10). Debridement of devitalized or infected tissue by scalpel, collagenases, or even maggots [55], promotes wound healing. Antibiotics may be required to treat infection to prevent osteomyelitis. Avoiding pressure on the wound (e.g., off-loading the foot) also assists wound healing [56]. The local temperature of the limb can be increased using sheepskin (Rooke) boots and may improve superficial collateral flow to help perfuse a limb [57]. Negative pressure dressings (e.g., vacuum-assisted) increase capillary flow and help

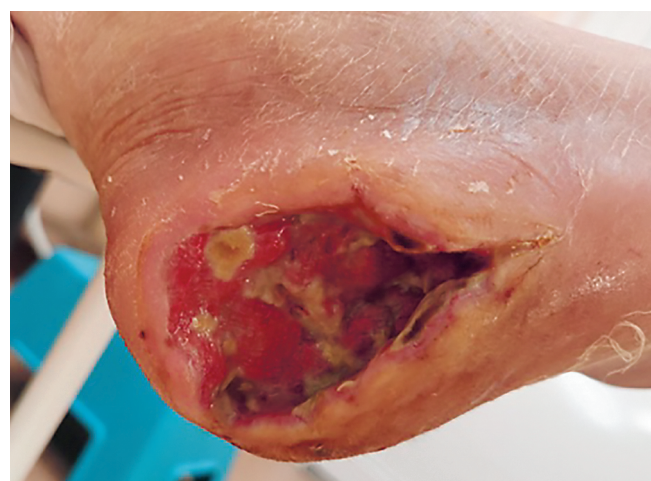

Рис. 10. *St. localis* на момент выписки. Активно гранулирующая рана правой пяточной области. На третьи сутки после ревазуляризации выполнена этапная некрэктомия трофической язвы правой пяточной области. Далее два курса NPWT-терапии. Рана очистилась, активно гранулирует. Пациент выписан на амбулаторное лечение на 62-е сутки госпитализации.

Fig. 10. *St. localis* at the time of discharge. Actively granulating wound of the right heel area. On the third day after revascularization, a staged necrectomy of the trophic ulcer of the right calcaneal region was performed. Next two courses of NPWT therapy was done. The wound has cleaned up and is actively granulating. The patient was discharged for outpatient treatment on the 62nd day of hospitalization

drain wounds [58]. Hyperbaric oxygen therapy offers no advantages for amputation prevention, but may improve the more subjective endpoint of wound healing in diabetes [59].

In patients where there are no revascularization options, intermittent pneumatic compression may assist wound healing and prevent major amputation [54]. To date, cell-based therapies such as infusion of bone marrow derived mononuclear cells have not prevented major amputation in patients with no revascularization options [60].

MEDICAL THERAPY AND SURVEILLANCE AFTER REVASCULARIZATION

Failure of endovascular and surgical treatment of CLTI due to thrombosis, neointimal proliferation, or progression in atherosclerosis demands close surveillance of patients by providers with vascular expertise. Surveillance also includes intensively treating risk factors for atherosclerosis to reduce the high risk of cardiovascular events.

Recurrent ischemic pain in the leg, lack of progression in wound healing, or a decline in ABIs are indicators of restenosis or occlusion. Duplex ultrasound of bypass grafts is commonly practiced to identify graft stenoses for revision and preserve long-term patency. However, this practice was not associated with lower amputation or better patency in one randomized trial [61], and there are no randomized trials of its value after endovascular therapy. Our practice after endovascular therapy includes a history and exam, and to use duplex ultrasound in the femoral artery particularly after treating long segment disease or when symptoms or poor wound healing raise concerns of patency [62, 63].

Evidence for therapies to prevent thrombosis or restenosis after endovascular interventions is sparse and often extrapolated from studies of coronary artery interventions. Low-dose aspirin is usually given for life to prevent thrombosis of a treated segment, but also other cardiovascular events. The duration of clopidogrel to prevent occlusion of segments treated by endovascular techniques is uncertain. Most clinical trials of bare-metal stenting use dual-antiplatelet therapy for 1–3 months [19–21, 24], but data extrapolated from medical studies of patients with peripheral artery disease, could justify longer treatment [64]. Clinical studies from Japan suggest that cilostazol may reduce in-stent restenosis [65–67], but this is not yet incorporated in recent guidelines of revascularization for CLTI.

The value of anticoagulation for lower extremity bypass is conflicting with some trials showing benefit over aspirin for autogenous vein versus prosthetic conduit and vice-versa [18]. Given the increased risk of bleeding, most surgeons reserve anticoagulation for graft thrombosis, or hypercoagulable disorders. There is no benefit of adding clopidogrel to aspirin for graft patency [68].

Evidence for the value of intensive atherosclerosis risk factor reduction is derived largely from observational studies and subgroups of patients with PAD in clinical trials. For example, PAD patients who stop smoking have fewer cardiovascular events than those who continue smoking [69, 70, 84, 92, 93]. Antiplatelet therapy with aspirin [71, 72] or clopidogrel [73, 85], and angiotensin converting enzyme inhibitors [74] decrease cardiovascular events in patients with PAD. Intensive statin therapy consistently lowers

cardiovascular events in PAD patients compared to no statin or low intensity statins [75–77]. In observational studies of patients receiving revascularization for PAD, statin therapy is associated with lower risks of cardiovascular events [63, 78–80], and limb loss [63, 81, 82, 84–93]. In population studies, intensive risk factor modification in patients with peripheral artery disease is improving, but still lags behind its use in patients with symptomatic coronary disease [83].

CONCLUSIONS

Patients with CLTI have a high risk of limb loss without revascularization and a high short term risk of cardiovascular events compared to less severe forms of chronic peripheral artery disease. Revascularization is indicated if it will prevent limb loss and preserve ambulation and function, while intensive medical therapy targets the risk factors for atherosclerosis progression and cardiovascular events. Endovascular revascularization offers a lower initial risk than open surgery, but recurrent disease from restenosis is common in patients with CLTI. New drug-eluting balloons and stents offer better longer-term outcomes after some endovascular revascularizations, but further long-term data on durability is required in order to assess their overall benefit given the increased costs of initial treatment. Close follow-up focusing on wound care and prevention, risk factor management, and surveillance for new and recurrent disease is required.

ДОПОЛНИТЕЛЬНАЯ ИНФОРМАЦИЯ

Вклад авторов. Все авторы внесли существенный вклад в разработку концепции и подготовку статьи, прочли и одобрили финальную версию перед публикацией.

Конфликт интересов. Авторы декларируют отсутствие явных и потенциальных конфликтов интересов, связанных с публикацией настоящей статьи.

Источник финансирования. Авторы заявляют об отсутствии внешнего финансирования.

ADDITIONAL INFORMATION

Author contribution. Thereby, all authors made a substantial contribution to the conception of the work, acquisition, interpretation of data for the work, drafting and revising the work, final approval of the version to be published and agree to be accountable for all aspects of the work.

Competing interests. The authors declare that they have no competing interests.

Funding source. This study was not supported by any external sources of funding.

ЛИТЕРАТУРА / REFERENCES

1. Hirsch A.T., Haskal Z.J., Hertzner N.R. et al. ACC/AHA 2005 Practice Guidelines for the management of patients with peripheral arterial

- disease (lower extremity, renal, mesenteric, and abdominal aortic): a collaborative report from the American Association for Vascular Surgery/Society for Vascular Surgery, Society for Cardiovascular Angiography and Interventions, Society for Vascular Medicine and Biology, Society of Interventional Radiology, and the ACC/AHA Task Force on Practice Guidelines (Writing Committee to Develop Guidelines for the Management of Patients With Peripheral Arterial Disease): endorsed by the American Association of Cardiovascular and Pulmonary Rehabilitation; National Heart, Lung, and Blood Institute; Society for Vascular Nursing; TransAtlantic Inter-Society Consensus; and Vascular Disease Foundation. *Circulation*. 2006; 113: e463–654.
2. Norgren L., Hiatt W.R., Dormandy J.A. et al. Inter-society consensus for the management of peripheral arterial disease. *Int Angiol*. 2007; 26: 81–157.
 3. Thukkani A K , Kinlay S. Endovascular intervention for peripheral artery disease. *Circulation research*. 2015; 116: 1599–613.
 4. Conte M.S., Geraghty P.J., Bradbury A.W. et al. Suggested objective performance goals and clinical trial design for evaluating catheter-based treatment of critical limb ischemia. *Journal of vascular surgery*. 2009; 50: 1462–73. e1–3.
 5. European Stroke. Tenders M., Aboyans V. Bartelink M.L. et al. Guidelines ESC CFP. ESC Guidelines on the diagnosis and treatment of peripheral artery diseases: Document covering atherosclerotic disease of extracranial carotid and vertebral, mesenteric, renal, upper and lower extremity arteries: the Task Force on the Diagnosis and Treatment of Peripheral Artery Diseases of the European Society of Cardiology (ESC) *European heart journal*. 2011; 32: 2851–906.
 6. Labs K.H., Dormandy J.A., Jaeger K.A. et al. Transatlantic Conference on Clinical Trial Guidelines in Peripheral Arterial Disease: clinical trial methodology. Basel PAD Clinical Trial Methodology Group. *Circulation*. 1999; 100: e75–81.
 7. Patel M.R., Conte M.S., Cutlip D.E. et al. Evaluation and treatment of patients with lower extremity peripheral artery disease: consensus definitions from Peripheral Academic Research Consortium (PARC). *J Am Coll Cardiol*. 2015; 65: 931–41.
 8. Ubbink D.T., Spincemaille G.H., Reneman R.S., Jacobs M.J. Prediction of imminent amputation in patients with non-reconstructible leg ischemia by means of microcirculatory investigations. *Journal of vascular surgery*. 1999; 30: 114–21.
 9. Rutherford R.B., Baker J.D., Ernst C. et al. Recommended standards for reports dealing with lower extremity ischemia: revised version. *Journal of vascular surgery*. 1997; 26: 517–38.
 10. Apelqvist J., Castenfors J., Larsson J. et al. Prognostic value of systolic ankle and toe blood pressure levels in outcome of diabetic foot ulcer. *Diabetes Care*. 1989; 12: 373–8.
 11. Ubbink D.T., Tulevski I.I., de Graaff J.C. et al. Optimisation of the non-invasive assessment of critical limb ischaemia requiring invasive treatment. *European journal of vascular and endovascular surgery: the official journal of the European Society for Vascular Surgery*. 2000; 19: 131–7.
 12. de Graaff J.C., Ubbink D.T., Legemate D.A. et al. Evaluation of toe pressure and transcutaneous oxygen measurements in management of chronic critical leg ischemia: a diagnostic randomized clinical trial. *Journal of vascular surgery*. 2003; 38: 528–34.
 13. Mills J.L., Conte M.S., Armstrong D.G. et al. Society for Vascular Surgery Lower Extremity Guidelines C. The Society for Vascular Surgery Lower Extremity Threatened Limb Classification System: risk stratification based on wound, ischemia, and foot infection (WIFI). *Journal of vascular surgery*. 2014; 59: 220–34. e1–2.
 14. Adam D.J., Beard J.D., Cleveland T. et al. Bypass versus angioplasty in severe ischaemia of the leg (BASIL): multicentre, randomised controlled trial. *Lancet*. 2005; 366: 1925–34.
 15. Oresanya L., Zhao S., Gan S. et al. Functional outcomes after lower extremity revascularization in nursing home residents: a national cohort study. *JAMA Intern Med*. 2015; 175: 951–7.
 16. Todd D.J., Kagan A., Chibnik L.B., Kay J. Cutaneous changes of nephrogenic systemic fibrosis: predictor of early mortality and association with gadolinium exposure. *Arthritis and rheumatism*. 2007; 56: 3433–41.
 17. AbuRahma A.F., Hayes J.D., Flaherty S.K., Peery W. Primary iliac stenting versus transluminal angioplasty with selective stenting. *Journal of vascular surgery*. 2007; 46: 965–70.
 18. Slovut D.P., Lipsitz E.C. Surgical technique and peripheral artery disease. *Circulation*. 2012; 126: 1127–38.
 19. Krankenberg H., Schluter M., Steinkamp H.J. et al. Nitinol stent implantation versus percutaneous transluminal angioplasty in superficial femoral artery lesions up to 10 cm in length: the femoral artery stenting trial (FAST). *Circulation*. 2007; 116: 285–92.
 20. Schillinger M., Sabeti S., Loewe C. et al. Balloon angioplasty versus implantation of nitinol stents in the superficial femoral artery. *N Engl J Med*. 2006; 354: 1879–88.
 21. Laird J.R., Katzen B.T., Scheinert D. et al. Nitinol stent implantation versus balloon angioplasty for lesions in the superficial femoral artery and proximal popliteal artery: twelve-month results from the RESILIENT randomized trial. *Circulation Cardiovascular interventions*. 2010; 3: 267–76.
 22. Scheinert D., Scheinert S., Sax J. et al. Prevalence and clinical impact of stent fractures after femoropopliteal stenting. *J Am Coll Cardiol*. 2005; 45: 312–5.
 23. George J.C., Rosen E.S., Nachtigall J. et al. SUPERA interwoven nitinol Stent Outcomes in Above-Knee Interventions (SAKE) study. *J Vasc Interv Radiol*. 2014; 25: 954–61.
 24. Dake M.D., Ansel G.M., Jaff M.R. et al. Paclitaxel-eluting stents show superiority to balloon angioplasty and bare metal stents in femoropopliteal disease: twelve-month Zilver PTX randomized study results. *Circulation Cardiovascular interventions*. 2011; 4: 495–504.
 25. Cassese S., Byrne R.A., Ott I. et al. Paclitaxel-coated versus uncoated balloon angioplasty reduces target lesion revascularization in patients with femoropopliteal arterial disease: a meta-analysis of randomized trials. *Circulation Cardiovascular interventions*. 2012; 5: 582–9.
 26. Rosenfield K., Jaff M.R., White C.J. et al. Trial of a Paclitaxel-Coated Balloon for Femoropopliteal Artery Disease. *N Engl J Med*. 2015; 373: 145–53.
 27. Tepe G., Laird J., Schneider P. et al. Drug-coated balloon versus standard percutaneous transluminal angioplasty for the treatment

- of superficial femoral and popliteal peripheral artery disease: 12-month results from the IN.PACT SFA randomized trial. *Circulation*. 2015; 131: 495–502.
28. Liistro F., Grotti S., Porto I. et al. Drug-eluting balloon in peripheral intervention for the superficial femoral artery: the DEBATE-SFA randomized trial (drug eluting balloon in peripheral intervention for the superficial femoral artery). *JACC Cardiovascular interventions*. 2013; 6: 1295–302.
29. Krankenberg H., Tubler T., Ingwersen M. et al. Drug-Coated Balloon Versus Standard Balloon for Superficial Femoral Artery In-Stent Restenosis: The Randomized Femoral Artery In-Stent Restenosis (FAIR) Trial. *Circulation*. 2015; 132: 2230–6.
30. Lammer J., Zeller T., Hausegger K.A. et al. Heparin-bonded covered stents versus bare-metal stents for complex femoropopliteal artery lesions: the randomized VIASTAR trial (Viabahn endoprosthesis with PROPATEN bioactive surface [VIA] versus bare nitinol stent in the treatment of long lesions in superficial femoral artery occlusive disease). *J Am Coll Cardiol*. 2013; 62: 1320–7.
31. Ambler G.K., Radwan R., Hayes P.D., Twine C.P. Atherectomy for peripheral arterial disease. *The Cochrane database of systematic reviews*. 2014; 3: CD006680.
32. Biancari F., Juvonen T. Angiosome-targeted lower limb revascularization for ischemic foot wounds: systematic review and meta-analysis. *European journal of vascular and endovascular surgery: the official journal of the European Society for Vascular Surgery*. 2014; 47: 517–22.
33. Kawarada O., Yasuda S., Nishimura K. et al. Effect of single tibial artery revascularization on microcirculation in the setting of critical limb ischemia. *Circulation Cardiovascular interventions*. 2014; 7: 684–91.
34. Bosiers M., Scheinert D., Peeters P. et al. Randomized comparison of everolimus-eluting versus bare-metal stents in patients with critical limb ischemia and infrapopliteal arterial occlusive disease. *Journal of vascular surgery*. 2012; 55: 390–8.
35. Rastan A., Brechtel K., Krankenberg H. et al. Sirolimus-eluting stents for treatment of infrapopliteal arteries reduce clinical event rate compared to bare-metal stents: long-term results from a randomized trial. *J Am Coll Cardiol*. 2012; 60: 587–91.
36. Scheinert D., Katsanos K., Zeller T. et al. A prospective randomized multicenter comparison of balloon angioplasty and infrapopliteal stenting with the sirolimus-eluting stent in patients with ischemic peripheral arterial disease: 1-year results from the ACHILLES trial. *J Am Coll Cardiol*. 2012; 60: 2290–5.
37. Liistro F., Porto I., Angioli P. et al. Drug-eluting balloon in peripheral intervention for below the knee angioplasty evaluation (DEBATE-BTK): a randomized trial in diabetic patients with critical limb ischemia. *Circulation*. 2013; 128: 615–21.
38. Siablis D., Kitrou P.M., Spiliopoulos S. et al. Paclitaxel-coated balloon angioplasty versus drug-eluting stenting for the treatment of infrapopliteal long-segment arterial occlusive disease: the IDEAS randomized controlled trial. *JACC Cardiovascular interventions*. 2014; 7: 1048–56.
39. Zeller T., Baumgartner I., Scheinert D. et al. Drug-Eluting Balloon Versus Standard Balloon Angioplasty for Infrapopliteal Artery Revascularization in Critical Limb Ischemia: 12-Month Results From the IN.PACT DEEP Randomized Trial. *J Am Coll Cardiol*. 2014; 64: 1568–76.
40. Piyaskulkaew C., Parvataneni K., Ballout H. et al. Laser in infrapopliteal and popliteal stenosis 2 study (LIPS2): Long-term outcomes of laser-assisted balloon angioplasty versus balloon angioplasty for below knee peripheral arterial disease. *Catheter Cardiovasc Interv*. 2015; 86: 1211–8.
41. Schanzer A., Mega J., Meadows J. et al. Risk stratification in critical limb ischemia: derivation and validation of a model to predict amputation-free survival using multicenter surgical outcomes data. *Journal of vascular surgery*. 2008; 48: 1464–71.
42. Singh N., Sidawy A.N., DeZee K.J. et al. Factors associated with early failure of infrainguinal lower extremity arterial bypass. *Journal of vascular surgery*. 2008; 47: 556–61.
43. Conte M.S. Critical appraisal of surgical revascularization for critical limb ischemia. *Journal of vascular surgery*. 2013; 57: 8S–13S.
44. Pereira C.E., Albers M., Romiti M. et al. Meta-analysis of femoropopliteal bypass grafts for lower extremity arterial insufficiency. *Journal of vascular surgery*. 2006; 44: 510–7.
45. Schanzer A., Hevelone N., Owens C.D. et al. Technical factors affecting autogenous vein graft failure: observations from a large multicenter trial. *Journal of vascular surgery*. 2007; 46: 1180–90. discussion 1190.
46. Twine C.P., McLain A.D. Graft type for femoro-popliteal bypass surgery. *The Cochrane database of systematic reviews*. 2010: CD001487.
47. Pomposelli F.B., Kansal N., Hamdan A.D. et al. A decade of experience with dorsalis pedis artery bypass: analysis of outcome in more than 1000 cases. *Journal of vascular surgery*. 2003; 37: 307–15.
48. Lumsden A.B., Morrissey N.J. Comparison of S, Primary Patency Between the FBH-CVG and Co-investigators ES&T. Randomized controlled trial comparing the safety and efficacy between the FUSION BIOLINE heparin-coated vascular graft and the standard expanded polytetrafluoroethylene graft for femoropopliteal bypass. *Journal of vascular surgery*. 2015; 61: 703–12. e1.
49. Daenens K., Schepers S., Fourneau I. et al. Heparin-bonded ePTFE grafts compared with vein grafts in femoropopliteal and femorocrural bypasses: 1- and 2-year results. *Journal of vascular surgery*. 2009; 49: 1210–6.
50. Chang C.K., Scali S.T., Feezor R.J. et al. Defining utility and predicting outcome of cadaveric lower extremity bypass grafts in patients with critical limb ischemia. *Journal of vascular surgery*. 2014; 60: 1554–64.
51. Kinlay S. Outcomes for clinical studies assessing drug and revascularization therapies for claudication and critical limb ischemia in peripheral artery disease. *Circulation*. 2013; 127: 1241–50.
52. Menard M.T., Farber A. The BEST-CLI trial: a multidisciplinary effort to assess whether surgical or endovascular therapy is better for patients with critical limb ischemia. *Seminars in vascular surgery*. 2014; 27: 82–4.
53. Dormandy J., Heeck L., Vig S. Major amputations: clinical patterns and predictors. *Seminars in vascular surgery*. 1999; 12: 154–61.
54. Taylor S.M., Kalbaugh C.A., Blackhurst D.W. et al. Preoperative clinical factors predict postoperative functional outcomes after

- major lower limb amputation: an analysis of 553 consecutive patients. *Journal of vascular surgery*. 2005; 42: 227–35.
55. Enoch S., Grey J.E., Harding K.G. ABC of wound healing. Non-surgical and drug treatments. *BMJ*. 2006; 332: 900–3.
 56. Healy A., Naemi R., Chockalingam N. The effectiveness of footwear and other removable off-loading devices in the treatment of diabetic foot ulcers: a systematic review. *Current diabetes reviews*. 2014; 10: 215–30.
 57. Rooke T.W., Hollier L.H., Osmundson P.J. The influence of sympathetic nerves on transcutaneous oxygen tension in normal and ischemic lower extremities. *Angiology*. 1987; 38: 400–10.
 58. Eginton M.T., Brown K.R., Seabrook G.R. et al. A prospective randomized evaluation of negative-pressure wound dressings for diabetic foot wounds. *Annals of vascular surgery*. 2003; 17: 645–9.
 59. Kranke P., Bennett M., Roeckl-Wiedmann I., Debus S. Hyperbaric oxygen therapy for chronic wounds. *The Cochrane database of systematic reviews*. 2004: CD004123.
 60. Teraa M., Sprengers R.W., Schutgens R.E. et al. Effect of repetitive intra-arterial infusion of bone marrow mononuclear cells in patients with no-option limb ischemia: the randomized, double-blind, placebo-controlled Rejuvenating Endothelial Progenitor Cells via Transcutaneous Intra-arterial Supplementation (JUVENTAS) trial. *Circulation*. 2015; 131: 851–60.
 61. Davies A.H., Hawdon A.J., Sydes M.R. et al. Is duplex surveillance of value after leg vein bypass grafting? Principal results of the Vein Graft Surveillance Randomised Trial (VGST). *Circulation*. 2005; 112: 1985–91.
 62. Sobieszczek P., Eisenhauer A. Management of patients after endovascular interventions for peripheral artery disease. *Circulation*. 2013; 128: 749–57.
 63. Todoran T.M., Connors G., Engelson B.A. et al. Femoral artery percutaneous revascularization for patients with critical limb ischemia: outcomes compared to patients with claudication over 2.5 years. *Vasc Med*. 2012; 17: 138–44.
 64. Wong P.F., Chong L.Y., Mikhailidis D.P. et al. Antiplatelet agents for intermittent claudication. *The Cochrane database of systematic reviews*. 2011: CD001272.
 65. Iida O., Nanto S., Uematsu M. et al. Cilostazol reduces restenosis after endovascular therapy in patients with femoropopliteal lesions. *Journal of vascular surgery*. 2008; 48: 144–9.
 66. Soga Y., Iida O., Hirano K. et al. Restenosis after stent implantation for superficial femoral artery disease in patients treated with cilostazol. *Catheter Cardiovasc Interv*. 2012; 79: 541–8.
 67. Soga Y., Iida O., Kawasaki D. et al. Impact of cilostazol on angiographic restenosis after balloon angioplasty for infrapopliteal artery disease in patients with critical limb ischemia. *European journal of vascular and endovascular surgery: the official journal of the European Society for Vascular Surgery*. 2012; 44: 577–81.
 68. Belch J.J., Dormandy J., Committee C.W. et al. Results of the randomized, placebo-controlled clopidogrel and acetylsalicylic acid in bypass surgery for peripheral arterial disease (CASPAR) trial. *Journal of vascular surgery*. 2010; 52: 825–33. 833 e1–2.
 69. Faulkner K.W., House A.K., Castleden W.M. The effect of cessation of smoking on the accumulative survival rates of patients with symptomatic peripheral vascular disease. *The Medical journal of Australia*. 1983; 1: 217–9.
 70. Jonason T., Bergstrom R. Cessation of smoking in patients with intermittent claudication. Effects on the risk of peripheral vascular complications, myocardial infarction and mortality. *Acta Med Scand*. 1987; 221: 253–60.
 71. 2011 ACCF/AHA Focused Update of the Guideline for the Management of patients with peripheral artery disease (Updating the 2005 Guideline): a report of the American College of Cardiology Foundation/American Heart Association Task Force on practice guidelines. *Circulation*. 2011; 124: 2020–45.
 72. Berger J.S., Hiatt W.R. Medical therapy in peripheral artery disease. *Circulation*. 2012; 126: 491–500.
 73. A randomised, blinded trial of clopidogrel versus aspirin in patients at risk of ischaemic events (CAPRIE) CAPRIE Steering Committee. *Lancet*. 1996; 348: 1329–39.
 74. Klein A.J., Pinto D.S., Gray B.H. et al. SCAI expert consensus statement for femoral-popliteal arterial intervention appropriate use. *Catheter Cardiovasc Interv*. 2014; 84: 529–38.
 75. Klein A.J., Feldman D.N., Aronow H.D. et al. SCAI expert consensus statement for aorto-iliac arterial intervention appropriate use. *Catheter Cardiovasc Interv*. 2014; 84: 520–8.
 76. Bonvini R.F., Rastan A., Sixt S. et al. Endovascular treatment of common femoral artery disease: medium-term outcomes of 360 consecutive procedures. *J Am Coll Cardiol*. 2011; 58: 792–8.
 77. Aboyans V., Criqui M.H., Abraham P. et al. Measurement and interpretation of the ankle-brachial index: a scientific statement from the American Heart Association. *Circulation*. 2012; 126: 2890–909.
 78. Armstrong E.J., Chen D.C., Westin G.G. et al. Adherence to guideline-recommended therapy is associated with decreased major adverse cardiovascular events and major adverse limb events among patients with peripheral arterial disease. *Journal of the American Heart Association*. 2014; 3: e000697.
 79. Connors G., Todoran T.M., Engelson B.A. et al. Percutaneous revascularization of long femoral artery lesions for claudication: patency over 2.5 years and impact of systematic surveillance. *Catheter Cardiovasc Interv*. 2011; 77: 1055–62.
 80. O'Neil-Callahan K., Katsimaglis G., Tepper M.R. et al. Statins decrease perioperative cardiac complications in patients undergoing noncardiac vascular surgery: the Statins for Risk Reduction in Surgery (StaRRS) study. *J Am Coll Cardiol*. 2005; 45: 336–42.
 81. Henke P.K., Blackburn S., Proctor M.C. et al. Patients undergoing infrainguinal bypass to treat atherosclerotic vascular disease are underprescribed cardioprotective medications: effect on graft patency, limb salvage, and mortality. *Journal of vascular surgery*. 2004; 39: 357–65.
 82. Vogel T.R., Dombrovskiy V.Y., Galinanes E.L., Kruse R.L. Preoperative statins and limb salvage after lower extremity revascularization in the Medicare population. *Circulation Cardiovascular interventions*. 2013; 6: 694–700.
 83. Subherwal S., Patel M.R., Kober L. et al. Missed opportunities: despite improvement in use of cardioprotective medications among patients with lower-extremity peripheral artery disease, underuse remains. *Circulation*. 2012; 126: 1345–54.



84. Kuchay A.A., Lipin A.N., Antropov A.V. et al. Hybrid approach to long occlusion of SFA with CLTI. *Angiology and vascular surgery*. 2022; 28(S1): 161–3.
85. Kurianov P., Lipin A., Antropov A. et al. Popliteal artery angioplasty for chronic total occlusions with versus without the distal landing zone. *Annals of vascular surgery*. 2020; 62(68): 417–25.
86. Kuchay A.A., Lipin A. N., Antropov A.V. et al. Concept of a “DISTAL HYBRID” for long occlusions of the superficial femoral artery with severe damage to the outflow pathways at critical ischemia of the lower extremity. *Angiology and vascular surgery*. 2022; 28(S1): 157–61.
87. Kuchay A.A., Lipin A.N., Antropov A.V. et al. Hybrid approach in treatment of extended occlusive arteries of the lower extremities in CLTI. *Angiology and vascular surgery*; 2019; 25(S2): 260–4.
88. Kuchay A.A., Lipin A.N., Antropov A.V. et al. Treatment for multi-storey lesions of lower extremities in CLTI. *Angiology and vascular surgery*; 2021; 27(S2): 410–2.
89. Kuchay A.A., Lipin A.N., Karelina N.R. et al. Revascularization in extended occlusions of the superficial part of the femoral artery and multi-storey lesions of the arteries of the lower extremity. *Forcipe*. 2022; 5(3): 4–14.
90. Kuchay A.A., Lipin A.N., Karelina N.R., Artyukh L.Yu. Revascularization of lower limb based on the angiosome concept with early local flap reconstruction (A CASE REPORT). *Forcipe*. 2022; 5(4): 29–35.
91. Kuchay A.A., Lipin A.N., Antropov A.V. et al. Treatment of multilevel lesions of arteries in lower extremities in cases of CLTI. *Medical Alliance*. 2022; 10(S3): 187–9. EDN IWSMIP.
92. Kuchay A.A., Lipin A.N., Gruzdev N.N. et al. Lower extremity peripheral artery disease: contemporary epidemiology, management and future trends (a scientific statement). *Russian biomedical research (St. Petersburg)*. 2023; 8(4): 54–64.
93. Kuchay A.A., Lipin A.N. et al. The hybrid surgery concepts for atherosclerotic lesions of lower limb arteries Atherosclerosis and dyslipidemias. 2023; 3(52): 37–43.