

АУСКУЛЬТАЦИЯ ПРИ СЕРДЕЧНО-СОСУДИСТЫХ ЗАБОЛЕВАНИЯХ

© Юрий Иванович Строев, Леонид Павлович Чурилов

Санкт-Петербургский государственный университет. 199034, Санкт-Петербург, Университетская наб., д. 7–9.

Контактная информация: Леонид Павлович Чурилов — заведующий кафедрой патологии медицинского факультета, зам. руководителя лаборатории мозаики аутоиммунитета Санкт-Петербургского государственного университета, доцент, к. м. н. E-mail: elpach@mail.ru

Резюме. Данная публикация продолжает цикл авторских лекций, посвященных вопросам пропедевтики внутренних болезней, в первую очередь — на материале сердечно-сосудистой, эндокринной и бронхолегочной патологии. Пропедевтика толкуется авторами широко как введение во внутреннюю медицину, поэтому лекции содержат и терапевтический, и клинко-патофизиологический материалы. Лекция сопоставляет достижения и традиции отечественной терапевтической школы с принципами преподавания внутренней медицины, сложившимися в практике зарубежного медицинского образования. В шестой части рассматривается история и техника аускультации во взрослой и педиатрической практике, методология выслушивания аускультативных данных и их интерпретации применительно к сердечно-сосудистой патологии (рис. — 9, библиография — 24 ист.).

Ключевые слова: аускультация; сердечно-сосудистые заболевания; кошачье мурлыканье; ритм галопа; сосудистый шум; стетоскоп; тоны сердца; тоны Короткова; физикальное обследование; сердечные шумы; фонендоскоп.

AUSCULTATION IN CARDIOVASCULAR DISEASES

© Yuri I. Stroeve, Leonid P. Churilov

Saint Petersburg State University. 199034, Saint Petersburg, bld. 7–9, Universitetskaya embk.

Contact information: Leonid P. Churilov — M. D., Ph. D., Full Member of the International Academy of Sciences (Health and Ecology), Assoc. Prof., Chairman of Pathology Dept., Faculty of Medicine, Deputy-Head of the Laboratory of Mosaic of Autoimmunity, Saint-Petersburg State University, E-mail: elpach@mail.ru

Abstract. This publication continues a series of authorial lectures devoted to questions of Propaedeutics of Internal Diseases, primarily based on the material of cardiovascular, endocrine and bronchopulmonary diseases. Propaedeutics is widely interpreted by authors as an Introduction to Internal Medicine; therefore, these lectures also contain clinical pathophysiologic material. The lectures compare the achievements and traditions of Russian classical therapeutic school with the principles of Internal Medicine that have evolved in the practice of foreign medical education. The forth lecture is dedicated to history and methodology of auscultation in adult and paediatric practice and its data interpretation related to cardiovascular pathology (9 figs, bibliography — 24 references).

Keywords: auscultation; cardiovascular diseases; gallop rhythm; heart murmurs; heart sounds; Korotkov sounds; phonendoscope; physical examination; purring thrill; stethoscope; vascular murmur.

INTRODUCTION

Any physical body moving within air or fluid produces mechanical waves, easily transmitted through solid media also. When these waves reach our ears, we can hear sounds. The motions of inner organs themselves and turbulent movement or splash of the fluids within our body also produce sounds. Sound (including

ultrasound) is a great source of diagnostic information for a physician. *Auscultation* (from Latin verb: *auscultare* which means "to listen") is listening to the internal sounds of the body, directly (by ear) or indirectly, i. e. using a special device, like stethoscope or phonendoscope (unlike the former, the later one has a diaphragm or membrane amplifying the sounds (fig. 1).



Fig. 1. I.A. Tikhov (1927–1982). N.I. Pirogov examines D.I. Mendeleev (Oil, canvas. Vinnitsa, Museum-estate of N.I. Pirogov)



Fig. 2. Immediate auscultation in Paediatrics (Sculpture "Doctor and Patient" by I.Ya. Ginzburg (1859–1939). Painted plaster. Saint Petersburg State Paediatric Medical University)

This historical event took place on October, 1855. In that period future discoverer of periodic law Dmitriy Ivanovich Mendeleev (27 January 1834, Tobol'sk, Russian Empire — 20 January 1907, Saint Petersburg, Russian Empire) had just graduated from St. Petersburg University and was a modest schoolteacher of Chemistry in Sevastopol gymnasium. He went to Crimea because of recommendations of some doctors, who had diagnosed tuberculosis in him, basing on few episodes of blood expectorating. Great surgeon and anatomist Nikolay Ivanovich Pirogov (25 November 1810, Moscow, Russian Empire — 5 December 1881, Vishnya, near Vinnitsa, Russian Empire) just before that period took part in Crimean (Eastern) War as a battle surgeon. After profound physical examination he ruled out the misdiagnosis of tuberculosis and related the symptoms found earlier in the patient to congenital vascular abnormalities, promising that the patient will live a long life. Both forecast and diagnosis made by genius surgeon were true: Dimitry Ivanovich Mendeleev lived almost 52 years after that episode and never suffered from tuberculosis. The symptoms revealed in Mendeleev's case were related to non-syndromal connective tissue dysplasia.

Medical doctors may auscultate sound phenomena derived from circulatory and respiratory systems (heart, blood vessel and breath sounds and murmurs), as well as from the gut (gastric and bowel sounds) [22].

HISTORICAL ASPECTS

Even Ancient clinicians already used to listen to inner sounds produced by patient's bodies — but they did it immediately with their ears [fig. 2]

The father of European Medicine, a Greek physician Hippocrates of Cos (circa 460 B. C. — circa 370 B. C.) described several diagnostic sounds related to disorders of respiratory system: Among them those meaningful until now, like: Pleural friction rub, splash murmur after chest succussion in hydrothorax and some breathe râles. The first documented medical immediate auscultation of the heart sounds belonged to Greek physician Aretaeus of Cappadocia (1st century — first half of 2nd century A. D.).

The mediate auscultation by an original wooden-made device, which author named *stethoscope* (from Greek words: chest+ exploring) was invented and introduced by a French physician Rene-Theophile Hyacinthe Laennec (17 February 1781, Quimper, France — 13 August 1826, Ploare, France). Recently the medical world celebrated bicentennial of the most useful medical invention in history.

R. Laennec's outstanding personality and unique medical education he obtained — taken together, for sure, predetermined such an exclusive contribution into medical science made by a man whose life, unfortunately, was very short due to tuberculosis. Young Rene-Theophile after death of his mother (who died from the same disease, spread on her son in childhood) since the age of 12 had to live with his uncle, Guillaume-Francois who was skillful physician and medical teacher at University. The uncle gave him first lessons of Medicine, partially while treated his nephew, whose health was poor from the very childhood. A talented boy absorbed a lot of medical information and learned

German, Greek and Latin languages while still a child. He was also an amateur of poetry. Later, being a medical student in University of Paris, R.-Th. H. Laennec was lucky to be a close pupil of outstanding doctors and clinical pathologists [22]: A leading physician of the epoch, inculcator of percussion J.-N. Corvisart (see [8]) and great surgeon and anatomist baron Guillaume Dupuytren (5 October 1777, Pierre-Buffiere, France — 8 February 1835, Paris, France) instructed him. The leading pathologist of the world Marie-Francois-Xavier Bichat (born 11/14 November, 1771, Thoirette, France — 22 July, 1802, Lyon, France) greatly impressed him with his course of Pathology. All these teachers always tried to correlate clinical manifestations of diseases to the data of Anatomic Pathology, because autopsy became common in French hospitals very early — since Napoleon's times. But anatomic data from dead bodies were not sufficient in order to comprehend the live dynamics of disease and judge upon its mechanisms. Laennec made the next step: He attempted to correlate symptoms of chest diseases to physiologic processes in functioning organs of the body, thus putting an important founding stone into fundament of Clinical Pathophysiology.

In 1816 he invented stethoscope and started systematic correlative studies of sound phenomena registered in chest diseases in regards to their manifestations and diagnosis. Working at the Necker-Enfants Malades Hospital in Paris, he coined almost all

basic terms for auscultation phenomena and published a synopsis of his method and results in a book of 1819 [13]. Unlike percussion [20], mediate auscultation was very soon broadly accepted by French and international medical communities, which brought global fame to the young doctor. Like Antonio Stradivari in violin making, Rene Laennec who improved step by step the construction of his stethoscope became the most recognized producer of new medical devices worldwide, and by the moment of his death almost all stethoscopes in function in Europe were made by Laennec's hands (fig. 3) [22, 23].

In Russia first experience of mediate auscultation was acquired and broadly spread by professor of military Emperor's Medical Surgical Academy in Saint Petersburg — Prokhor Alekseevich Charukovsky (1790, Pologi, near Poltava, Russian Empire — 11 June 1842, Saint Petersburg, Russian Empire) [4] (fig. 4).

His first papers on new method appeared in 1824. Another great contribution into development of auscultation belonged to founder of Rheumatology, another Russian physician Grigory Ivanovich Sokol'sky (24 March 1807, Moscow, Russian Empire — 12 March 1886, Moscow, Russian Empire) (Fig. 4). He was an alumnus of Dörpat University and a classmate of N. I. Pirogov, interested not only in Medicine, but also in Physics and after postgraduate studies in Western Europe worked at Kazan and Moscow Universities, where he authored a lecture "On the investigation of diseases by hearing and stethoscope" (1835) and a guide in chest maladies (1838) with a detailed description of acoustic manifestations of heart valve diseases [18].

Later in XIX age stethoscope was stepwise modified and amended. First prototype looked like a simple trumpet (fig. 3). Soon its flexible version was suggested by... a medical student: Nicholas P. Comings in Scotland (1829). It is not quite clear, if he suggested binaural instrument, or monaural, like the first one [22, 7]. A British physician (and one of the first biophysicists) — Golding Bird (9 December 1814–27 October 1854) improved its



Fig. 3. R.-Th. H. Laennec and his original stethoscope (from Science Museum, London)




Fig. 4. Russian pioneers of auscultation: P.A. Charukovsky (left) and G.I. Sokol'sky. The later also pioneered the use of finger-pleximeter instead of pleximeter devices in percussion

construction in a single-earpiece version (1840) [2]. First binaural modification with gutta-percha tubes was suggested in 1851 by an Irish physician and orientalist-traveler Arthur Leared (1822, Wexford, Ireland, British Empire — 16 October 1879, London, England, British Empire). He presented new modification of stethoscope at the world exhibition in London. But, he has published his priority in a formal paper only after return from Crimean War, that particular war after which N.I. Pirogov did auscultate young D.I. Mendeleev (fig. 1) with an old-fashioned device [14]. A bit later (1856) an inventive American doctor George Philip Cammann (7 September 1804, New York, USA — 11 February 1863, New York, USA) proposed the bell-shaped head (as a better resonator) for the binaural stethoscopes. A British medical scholar (worked also in USA) — Somerville Scott Alison (1813–1877) in 1858 invented so called stethophone — a differential binaural stethoscope with two bells — for simultaneous auscultation from two spots. He also is claimed to be founder of Telemedicine, because of his experiment in 1860 in Boston with telegraphic translation of sphygmographic data to the distance of 3 miles with its synchronous diagnostic evaluation “by correspondence”.

An outstanding German clinician and one of the early clinical pathophysiologists Ludwig Traube¹ amended the shape and acoustic quality of the stiff monaural stethoscope (fig. 5, left). Traube's model became most popular among one-earpiece ones.

Finally, an American engineer Robert C.M. Bowles (1850–1919) suggested in 1894 (and patented in 1901) a flat stethoscope (fig. 5, right) with a diaphragm for sound enhancing, and thus in fact converted plain binaural stethoscope into device called in continental Europe phonendoscope.

A combination of Bowles' instrument with a bell-shaped classic stethoscope joined together on the end of binaural auscultative device (looking like double-sided coin) was finally proposed in 1929 by an American medical scholar Howard Sprague (1895–1970). The Bowles-Sprague stethoscope-phonendoscope (fig. 5, right) became worldwide popular standard model [22, 3]. A stethoscopic side is for better listening to sounds of lower frequencies and phonendoscopic one — for higher sounds. In the picture below (fig. 6) you can see paediatric auscultation by means of light modification of gutta-percha binaural flexible stethoscope-phonendoscope in practice of a Soviet rural physician. Light paediatric modification of stethoscope was first suggested by a Russian clinician

¹ Traube, Ludwig — a German internist and clinical pathophysiologist, born January 12, 1818, Ratibor in Oberschlesien; died April 11, 1876, Berlin, Germany [9].



Fig. 5. Two variants of stethoscope construction. Left: Traube's monaural stiff model of stethoscope produced in mid-XX century (box-wood). Left to right: In disassembled, "marsh" and functional states (from the private collection of Y.I. Stroev). Right: Bowles' binaural flexible model (from Museo de Medicina Infanta Margarita, Madrid. Open Gallery)



Fig. 6. N.A. Plastov (1930–2000). "Doctor" (Oil, canvas, 1966. Achinsk Museum and Exhibition Centre, Achinsk)

Nil Feodorovich Filatov (2 June 1847, Mikhailovka near Penza, Russian Empire — 8 February 1902, Moscow, Russian Empire).

In XX and XXI centuries very advanced technical modifications of the auscultation devices appeared, like electronic stethoscopes with sound pen-recorders, digital computer-aided ones

and even Doppler ultrasound stethoscopes or 3D-printed ones. By the way, in the clinic headed by a disciple of G.F. Lang and M.V. Chernorutsky, the famous cardiologist and biophysicist professor Aleksei Alekseevich Kedrov (23 September 1906 Saint Petersburg, Russian Empire — 2 September 2004, Saint Peters-

burg, Russian Federation), who was an academic supervisor for one of the authors of this lecture (YIS) and teacher of Internal Medicine for another author (LPCh), was designed and tested the first electronic stethoscope in the USSR, as well as the world's first devices for registering breathing sounds and automatic ECG analysis constructed especially for mass population medical check-ups. These devices were demonstrated at the world exhibition of 1967 in Montreal (Canada) [19]. Nevertheless, in view of any technical achievements the physiologic and pathophysiologic processes responsible for auscultation phenomena remain the same, as well as diagnostic correlations and basic doctor's skills necessary for the application of this method. Medical doctors will not put aside their acoustic stethoscopes in the nearest future. The device became one of the symbols of medical profession.

HEART SOUNDS AUSCULTATION

The heart is to be auscultated, if possible, both in vertical and horizontal positions of a patient. When patient's general condition permits, it is desirable also to perform auscultation after special physical effort tests (running, bicycle ergometry, knees-bend squatting etc.) [5, 10, 11, 21]. Heart auscultation by stethoscope usually reveals two rhythmic reiterating tones (heart sounds). Immediate auscultation by ear, as a rule, signs up also 3rd sound (following the 2nd one), which is much weaker, than other sounds and presents not only audible, but also tangible phenomenon. The 1st heart sound is named systolic, the 2nd one is diastolic, the space between them is systolic pause (normally, it lasts for 0.2 sec); the space after the 2nd sound, before the 1st one is diastolic pause (normally, it lasts for 0.43 sec). The heart sounds are complexes combined from several audible constituents. Thus, the 1st sound is an integrative of the following eight sources: Synchronous contraction of both ventricles, coincident closure of both mitral and tricuspid valves, combined opening of both aortic and pulmonary artery orifices, and distension of their orifices; and the muscle component, caused by both left and right atria contraction. In turn, the 2nd sound is formed by two phenomena: Simultaneous closure of aortic and pulmonary artery crescent valves [5, 11].

The 3rd sound is resulted from the injection of blood during the initial phase of diastole from the atria into emptied, dilating ventricle cavities, distending their walls. The 1st sound lasts 0.11–0.12 sec, the 2nd one — 0.7–0.8 sec. The 3rd sound is considered to be physiologic one up till 25 years of age, being more common in nervous persons and in heavy physical strain. In left ventricular insufficiency the 3rd sound is interpreted as abnormal. Its duration is 0.2–0.6 sec. As a result of its pathologic appearance, so called "gallop rhythm" may arise [6, 11].

Sporadically, in atria hypertrophy pre-systolic 4th heart sound may arise. This produces the phenomenon of pre-systolic "gallop rhythm". It is a matter of proficiency to distinguish the constituents of the sounds, because they vary in dependence on type and location of certain pathologic changes.

Every sound is advisable to auscultate at the point, located in maximal proximity to that heart ostium, which serves a source of this particular audible phenomenon.

Mitral valve's projection is at the point of 3rd left rib cartilage attachment to sternum. Tricuspid valve's projection is in the middle of sternum on the line, that joins the attachment points of 3rd right and 5th left ribs. Projection of aortic valve is on the level of 3rd ribs' attachment, in the middle of aorta. Pulmonary artery orifice's projection is in 2nd intercostal space near left margin of sternum bone. All the projections listed above are situated in closest vicinity. Thus, it is necessary to select the points of auscultation as to keep maximal loudness for the sound of attention and to weaken evidently all other sounds. That's why the stethoscope is positioned not exactly to the points of valve projections, but to some special loci determined by previous experience of the generations of clinicians.

Mitral sounds are spread well to cardiac apex, where apex beat (AB) is produced. Because of this, at first doctor has to palpate the AB [20], then place the stethoscope just on AB area. Normally, the 1st sound in apical point is louder than the 2nd one. The 1st sound coincides with carotid pulsation and with AB, thus named systolic sound. It is better to auscultate tricuspid valve over the base of processus xiphoideus. Crescent valves of aorta better to auscultate in right 2nd intercostals space near sternum.

The 2nd, diastolic sound is better to auscultate over the base of the heart, in projection point of aortic crescent valves.

The classic point for aortic valve auscultation is Botkin — Erb point². It is located at the focus of intersection between anatomical heart axis and left sternal edge. Sounds are more pronounced in vertical position of a patient. The emphasizing of a sound in a certain point is called accent. The accent of 1st sound over AB and accents of 2nd sound over aorta and pulmonary artery are of great clinical significance. The accent of 1st sound over apex is a classic and, sometimes, single sign of mitral stenosis. The same accent appears in extrasystoles, which produce slapping (cracking) 1st heart sound. The 1st heart sound accent is caused by small diastolic filling of left ventricle due to narrowing of atrio-ventricular aperture or results from premature contraction in response to extraordinary extrasystole. Aortic accent of 2nd sound is related to greater extent to systemic arterial hypertension, but may also occur in decreased aortic wall elasticity due to either atherosclerosis or aortitis of initial aortic portion, producing just local blood pressure elevation. In advanced atherosclerosis 2nd heart sound accent is of metallic character. In aortic insufficiency 2nd sound accent is not observable, in spite of high systolic pressure, due to incomplete closure of squeezed valves and their deformities, although sometimes the 2nd sound does not change in spite of aortic insufficiency. Neurocirculatory disorders in individuals with labile autonomous nervous system sporadically may be accompanied by aortic accent of the 2nd sound.

² Botkin, Sergey Petrovich (5 September 1832, Moscow, Russian Empire — 12 December 1889, Menton, France) — a Russian physician and clinical pathophysiologist, founder of the first lab specialized in Translational Medicine; Erb, Wilhelm Friedrich — a German neurologist, born November 30, 1840, Winnweiler, Bavarian Palatinate; died October 21, 1921, Heidelberg, Germany (here and in all footnotes below information is taken from [9]).

The 2nd heart sound accent over pulmonary artery is characteristic for lesser circulation hypertension (which may be observed in mitral valve diseases, pulmonary emphysema, severe kyphoscoliosis, pneumoniae, obvious pleural exudates). It is peculiar to all situations when lesser circulation is hardened, but right ventricle strength is still sufficient (compensated cor pulmonale).

The sounds are weakened in obese patients and in females with large breast, in pulmonary emphysema, in cachexia, in severe exhaustion, extreme fatigue, as well as in myocardial diseases (like myocarditis, primary or secondary cardiomyopathies). Cardiac muscle in these conditions is contracting in weaker and slower mode. The 2nd sound over large blood vessels may be weak in shock and collapse — with their decreased stroke volume. Sometimes it is not audible at all. The weakened 1st sound over cardiac apex is displayed in atrio-ventricular valve insufficiency, in surplus diastolic filling of ventricles, in slower ventricle contraction due to hypertrophy, in myocarditis, cardiosclerosis, or cardiomyopathies. In all these cases 1st heart sound becomes dull. Hydropericardium makes the heart sounds very dull. In slim, subtle individuals all the heart sounds are amplified, as well as in pneumosclerosis, during physical exercises, under stress or influence of excitatory drugs, and, especially — in hyperthyroidism. Similar changes may occur in fever, and in anemia. Thin chest wall, as well as existence of some sounding resonators (cavities filled up with air, next to heart: Lung caverns, pneumothorax, gut gases, big phrenic herniae etc) — all may lead to enhancement of heart sounds. Splitting of heart sounds (distinguished from 3rd and 4th sound appearance) is not uncommon finding [11]. Splitting of the 1st sound is a result of a non-synchronous contraction of right and left ventricles. This may result from isolated left or right bundle branch block (His³ bundle branch blockade), but also from separate hypertrophy of one ventricle. The 2nd sound spit is typical for non-synchronous end of left and right ventricle systole, producing some interval between aortic and pulmonary artery crescent valves closure. A striking example is mitral stenosis, when left ventricle takes for systole shorter time, than right one, and aorta is closed earlier than pulmonary artery. Sound splitting may be real or just apparent, produced by additional sounds. An example of additional sound is mitral valve opening click [15], which is arisen soon after 2nd sound, imitating its splitting. Unlike real spitted 2nd sound, this additional sound is audible best of all not over heart base, but over cardiac apex. The traditional name of this phenomenon is "mitral opening snap" [11]. In obstetric and paediatric practice during auscultation of the heart in infants (fig. 7), the accent or splitting of the 2nd heart sound is often found on the pulmonary artery, since the pulmonary artery trunk is located in them closer to the chest wall than in adults. This allows a physician to listen simultaneously to the sound of aortal valve closing. In the prone position, the pressure in the pulmonary

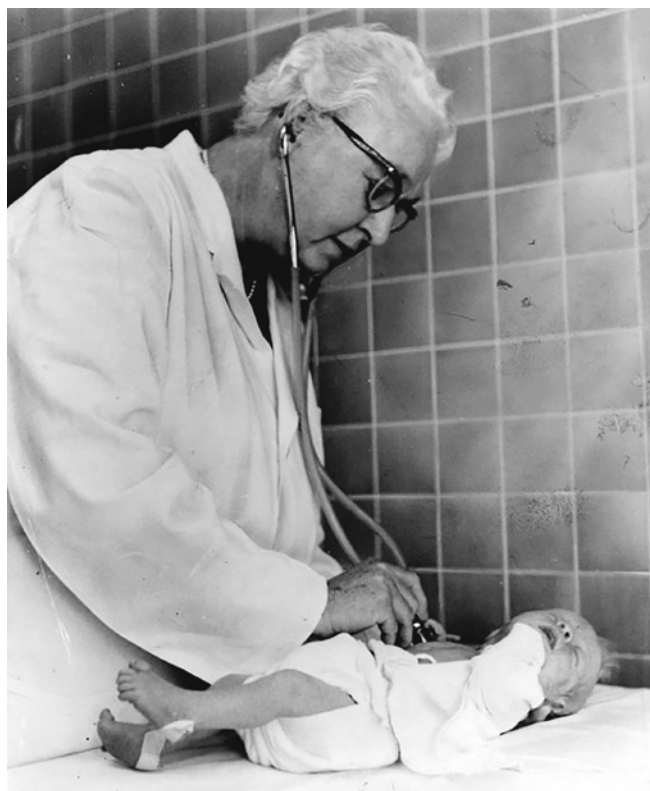

Fig. 7. Virginia Apgar (7 June, 1909, Westfield, USA — 7 August, 1974, New York, USA), an American obstetrical anesthesiologist, author of Apgar score (1953) during auscultation of an infant [6]

artery of an infant may increase, which is accompanied by an augment in the 2nd sound, since the musculature of the right heart in small children is relatively stronger than in adults. This is also the reason for the emphasis of the 2nd sound on the pulmonary artery or its bifurcation. If the accent is also maintained in the sitting or standing position, then doctor must take into account possibility of hypertension in a lesser circle of circulation. With increased breathing, the accent of the 2nd sound is not considered abnormal, because in these cases the pressure in the lesser circulation increases physiologically [1].

The 1st sound accent over AB plus mitral opening snap composes the classic melody of mitral stenosis. The 3rd and 4th sounds if enhanced, as it was mentioned above, produce three-tact rhythm of the heart or "gallop rhythm" [6]. Gallop rhythm is an appeal of a heart for help, it arises in noticeable weakness of myocardium contractility (infarction, non-compensated valve diseases, myocarditis, severe cardiosclerosis, arterial hypertension of essential or renal character — like in chronic nephritis) [5].

HEART MURMURS

Heart noises or murmurs — are of great significance in auscultating diagnosis. They may be delineated in three groups: organic, functional and dilatory ones [5].

³ His, Wilhelm — born July 9, 1831, Basel; died May 1, 1904. A Swiss anatomist and embryologist.

Organic ones are derived from valve lesions and, quite naturally, may occur in heart diseases, in papillary muscle rupture after myocardial infarction with acute mitral insufficiency.

Functional murmurs may be of cardiac and extracardiac origin, always non-related to valve diseases. They arise in anemia, sympathicotonia, and papillary muscle hypertonus which often is found in young persons with instability of autonomous nervous regulation. Presystolic (more rare — midsystolic) functional murmur is sporadically audible over projection point of mitral valve in patients with aortic insufficiency (Flint murmur⁴). It is low-pitched rumbling heart murmur, best heard at the cardiac apex [11, 12].

One of the murmurs of extracardiac origin is pericardial murmur due to fibrinous pericarditis and rough pericardial layers friction. It may be smooth or coarse. This murmur occurs also in chronic renal failure due to pericardial deposits of urates and other metabolites, in metastases of pericardial tumors, in severe dehydration, and quite often — in various systemic autoimmune diseases (e. g. in lupus erythematosus). It is heard also in post-infarction Dressler's syndrome⁵ (with anti-mitochondrial autoantibodies and polyserositis), sometimes in thyrotoxicosis or in heart contusion. Pericardial exudate leads to provisional disappearance of this murmur, but withdrawal of fluid allow it arise again. Its characteristics may be various (crisping, scratching, rustling etc). This murmur is recurrent and most pronounced over superficial cardiac dullness area, as a rule it enhances on bending ahead and, commonly, does not spread anywhere. Pericardial murmur must be distinguished from pleura-pericardial murmur, which is audible in relative cardiac dullness area. Pericardial murmur is kept when patients hold their breath, unlike pleura-pericardial one, which vanishes [5, 11, 12, 21].

Heart murmurs are less musical, than heart sounds, and more prolonged. It is the difficult item for verbal description that's why it is better to hear it at least once. The origin of the murmurs is stenotic, because laminar blood flow changes for turbulent one due to narrowing of lumen or heart orifices. Resulting vibration of heart valves and walls produces the murmurs. In valves insufficiency murmur is caused by blood regurgitation via improperly closed valve, thus the quicker is the blood flow, the louder is a murmur. In ghastly stenosis of valve as well as in cases of its extreme insufficiency the murmurs may be weak [5].

The murmurs may have various tunes: They resemble blowing, seesaw, rubbing, musical sounds, sometimes even with a kind of squeak. Physical effort provokes them due to acceleration of blood flow. Unlike the heart sounds, murmurs are stronger in horizontal position of a patient. There are following parameters of murmurs: Phase characteristic (systolic or diastolic), strength, duration, timbre, best heard spot, way of

spreading. All these characteristics are important in cardiologic diagnosis. The murmurs, like the sounds, may conduct long distance from place of origin, even to the back between scapulae (e. g. in aortic stenosis). Due to this it is important to find the point of their origin, displacing the stethoscope during auscultation towards the point of best hearing [5, 11, 12]. In general, the valve murmurs are best audible in valve sounds auscultation points. But, aortic murmurs are best for listening in aortic aperture projection point (see above). Pulmonary artery murmurs are extremely rare in adults, which is helpful in distinguishing diagnostics of aortic ones. The murmurs are easily spread along the direction of blood flow, but not counter blood flow [11]. Due to this the murmur of regurgitation in aortic insufficiency is not spread along aorta. If the loudness of a murmur increases as the stethoscope moves to AB, the murmur is probably of mitral origin. If the loudness is maximal on 3rd rib level over the middle of sternum, the murmur is of aortic origin. In combined heart diseases the murmurs, of course, are difficult for distinguishing. The remnants of normal sounds facilitate the diagnosis. The murmur in the moment of valve closure witnesses for its insufficiency. The murmur, corresponding the moment of valve opening is related to its stenosis. Organic systolic murmur over AB is a sign of mitral insufficiency, but diastolic one over the same point is a sign of mitral stenosis.

Valve lesions may be combined with one or another predominant component, forming the preponderance of corresponding murmur. Concerning the aortic valve diseases, insufficiency is manifested in diastolic, stenosis — in systolic murmur. Tricuspid disease rarely produces murmurs [5, 17, 21].

So, we may assume that apical systolic murmur is a manifestation of mitral insufficiency, basal systolic one — a manifestation of mitral stenosis. Diastolic murmur over cardiac apex is a sign of mitral stenosis, and the same diastolic murmur over heart base — is a sign of aortic insufficiency.

“FREMISEMENT CATAIRE” AND VASCULAR MURMURS

The murmurs may be not only auscultated, but also touchable. Purring thrill phenomenon (“fremissement cataire” — in French) is a sensation of trembling palpated, most often, in cases of mitral stenosis, by hand put on patient's chest. It is called so because of similarity with the sensation, experienced by hand, put on purring cat's back [6, 10]. The term is a legacy of famous French school of Medicine, which was leading in the world in first half of XIX century, when auscultation developed very rapidly. Presystolic flutter, formed near the mitral aperture is transferred to thoracic wall. Palpatory trembling or thrill in heart area is also perceptible in interventricular septal defects, accompanied by specific pansystolic murmur in 4th space near left sternal edge. The diastolic murmur over aortic base is observable not only in aortic insufficiency, but in open foramen ovale joining the atria.

It is common finding, because over 20% of people have at least minor defect of foramen ovale.

⁴ Flint, Austin — an American physician, born October 20, 1812, Petersham, USA; died March 13, 1886, Brooklyn, USA. The founder of Cardiology in USA.

⁵ Dressler, William (1890–1969) — a Polish, later — American cardiologist. Syndrome is described by him in 1956.

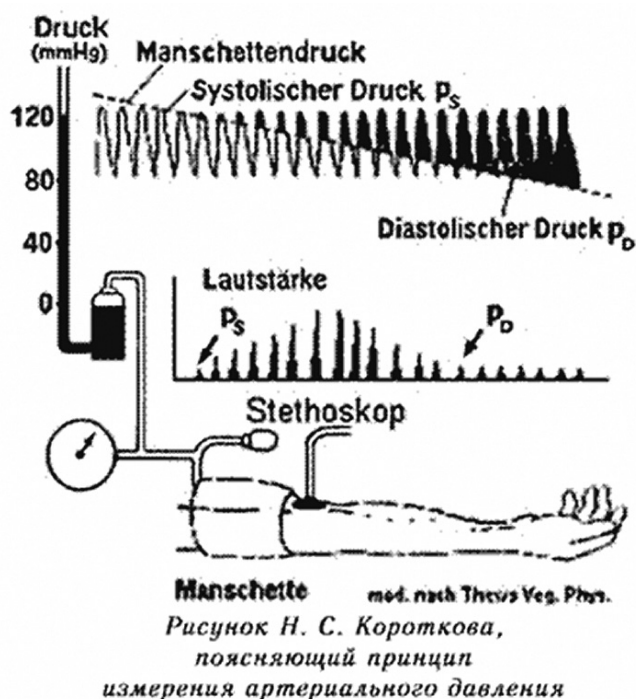


Fig. 8. Left: N.S. Korotkov, Russian surgeon, pioneer of modern vascular surgery. A portrait by N.F. Fomin. Right: original drawing by N.S. Korotkov explaining his method of arterial blood pressure measurement by means of auscultation [24]

The blood vessels are also a subject of auscultation [16]. Commonly, doctor may auscultate the vessels of middle caliber (carotid, subclavicular, or femoral arteries).

One has to palpate an artery firstly, then auscultate it by stethoscope. Do not press with the stethoscope on artery, because it will produce artificial stenosis and arise iatrogenic murmurs [5].

The murmurs of valve diseases, especially, those of aortic stenosis, are often spread along the large and mediocre caliber blood vessels.

The auscultation of vascular murmurs in abdominal area is of great importance for differential diagnosis of arterial hypertension. In disorder of renal arteries (caused by their atherosclerosis, arteriosclerosis, congenital stenosis or dysplasia) there is specific systolic murmur in the umbilical area. In congenital coarctation of abdominal aorta murmur is also obvious.

In aortic insufficiency high systolic blood pressure and big pulse difference may produce large fluctuations of vascular wall during systole and diastole. It results in Traube's double tone ("pistol shot") over femoral artery. Pressing upon this vessel by stethoscope produces Duroziez⁶ double murmur.

The 1st component of this murmur is produced by stenosis of the artery after pressing with the stethoscope, the 2nd one

⁶ Duroziez, Paul Louis — a French physician, born January 8, 1826, Paris, France; died January 16, 1897, Paris, France. Murmur was described by him in 1861.

results from the acceleration of backflow in diastole (blood regurgitation).

By far, the most important diagnostic sounds produced over blood vessel — are so called Korotkov⁷ sounds used worldwide for non-invasive routine measurement of arterial blood pressure on peripheral arteries. Korotkov sounds appear during turbulent blood flow via the brachial artery squeezed by cuff of the sphygmomanometer. They are auscultated over antecubital fossa. The moments of their appearance or disappearance correspond to the levels of systolic either diastolic arterial blood pressure. The phenomenon was discovered by Nikolay Sergeevich Korotkov (fig. 8). in 1905. The importance of this discovery for Medicine is difficult to overestimate. Not only had it allowed checking the patency of peripheral arteries, which was the primary aim of Korotkov's experiments. It made possible to control arterial blood pressure customarily and non-invasively and soon lead to understanding of the nature of shock, collapse and discovery of essential and secondary arterial hypertension diseases.

A healthy person usually does not have murmurs over veins. However a spinning top murmur auscultated over jugular veins and often observed in severe anemia, may be of some diagnostic

⁷ Korotkov, Nikolay Sergeevich — a Russian battle and vascular surgeon and clinical pathophysiological, born February 13, 1874, Kursk, Russian Empire; died 14 March 1920, Petrograd, RSFSR.

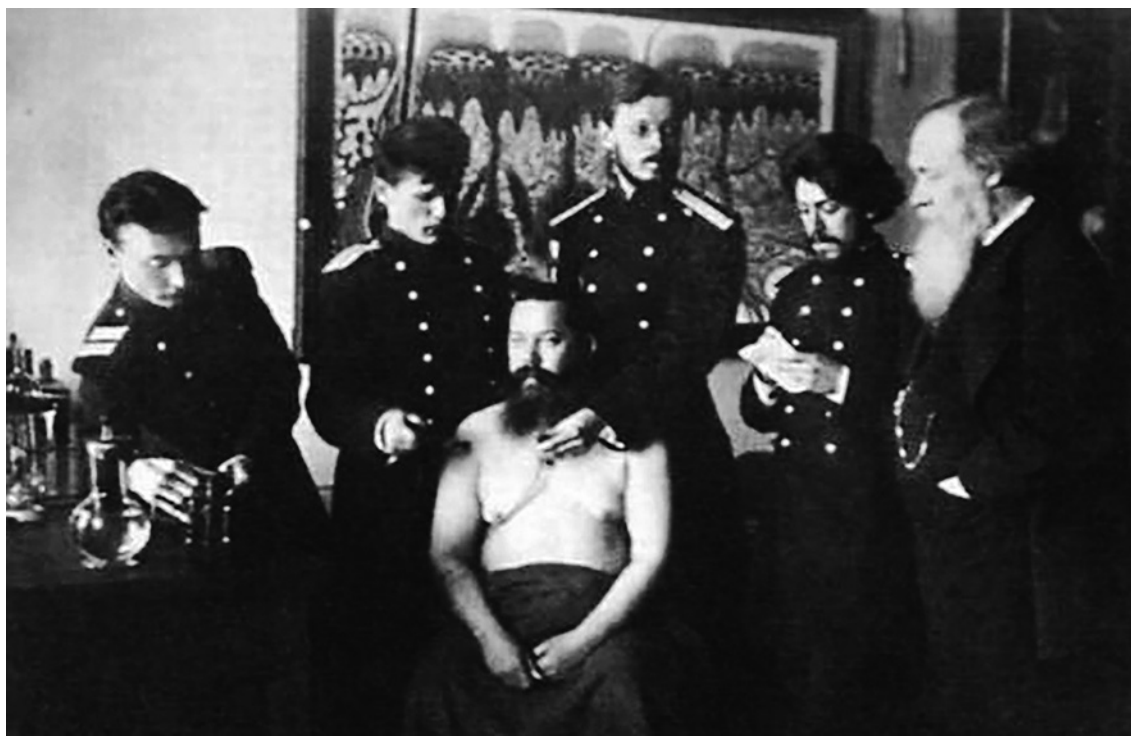

Fig. 9. Russian Emperor's Military Medical Academy. Class of auscultation. Standing left to right: unknown cadet, cadet Ivan Pavlov, cadet Sergei Lukyanov, cadet Vladimir Bekhterev, instructing Professor. St. Petersburg, 1883

significance. It has buzzing or blowing tune, more clear over right jugular vein and increases when patient turns his/her head to the left.

After completing the circulatory system examination [fig. 9], it is obligatory to check the status of other systems and organs also: Respiratory, digestive, urinary, endocrine etc. Only complex examination of the body as a whole may be helpful in diagnosis of any disease. There are no local diseases; unlike symptom or syndrome, every disease involves the whole body to a certain extent. Physical examination of other organ systems will be discussed in the next lectures. Only after careful physical examination medical doctor can proceed to laboratory and instrumental investigations, establishing the exact definitive diagnosis.

In conclusion, we would like to underline once more, that the plain physical methods of examination still have the biggest significance for diagnosis.

ACKNOWLEDGEMENT

Authors are grateful to their American students for whom this project was primarily intended, especially to Dr. S. G. Huneycutt M.D., F.A. A. F. P., D. C. and to untimely deceased Dr. William G. Scoggins M.D., B. A., D. C. (1948–2010) for their valuable help in preparation of these lectures and to renown Norwegian medical bibliographer and historian Dr. Ole Daniel Enersen for his titanic efforts supporting the comprehensive "Who named it?" database. No conflict of interest to declare. The authors equally contributed to the text.

REFERENCES/ЛИТЕРАТУРА

1. Auscul'tatsija u mladentsev s podezreniem na zabolevanie serdtsa. [Auscultation in infants with suspicion of cardiac disease]. URL: http://www.blackpantera.ru/diagnostika/29293/?PAGEN_1=3 (accessed: 8 August 2018) (in Russian) /Аускультация у младенцев при подозрении на заболевания сердца. Интернет-ресурс, URL: http://www.blackpantera.ru/diagnostika/29293/?PAGEN_1=3 (дата доступа: 8 августа 2018 г.)
2. Bird G. Advantages presented by the employment of a stethoscope with a flexible tube. London Medical Gazette, 11 December 1840; 1: 440–442.
3. Blaufox M.D. An Ear to the Chest: an Illustrated History of the Evolution of the Stethoscope. London: Parphenon Publishers, 2002: 149 p.
4. Charukovsky P.A. Obschaya patologicheskaya semiotika, ili uchenije o priznakah boleznej voobsche [General Pathologic Semiotics or the Doctrine of the General Signs of Diseases]. Saint Petersburg: Printhouse of Emperor's Orphanage, 1825: 251 p. (in Russian) / Чаруковский П.А. Общая патологическая семиотика, или учение о признаках болезней вообще. СПб.: тип. Императорского Воспитательного дома, 1825: 251 с.
5. Chernorutsky M.V. Dianostika vnutrennih boleznej [Diagnosis in Internal Medicine]. Leningrad: Medgiz Publishers, 1953: 182–190. (in Russian) / Чернолучский М.В. Диагностика внутренних болезней. Л.: «Медгиз», 1953. С. 182–190.
6. Churilov L.P., Stroeve Y.I., Kolobov A.V., Kolobova O.L., Konstantinova A.M., Utekhin V.J. Explanatory Dictionary of Selected

- medical Terms: Eponyms and Figurative Expressions [Tolkovy slovar' izbrannykh meditsinskih terminov. Epomimy i obraznye vyrazheniya]. Saint Petersburg: ELBI-SPb, 2010. 336 P. (in Russian) / Чурилов Л.П., Строев Ю.И., Колобов А.В., Колобова О.Л., Константинова А.М., Утехин В.И. Толковый словарь избранных медицинских терминов. Эпонимы и образные выражения. СПб.: ЭлБи-СПб, 2010. 336 с.
7. Comings N.P. A flexible stethoscope. *Lancet*, 29 August 1829.
 8. Corvisart J.N. Nouvelle methode pour reconnaitre les maladies internes de la poitrine par la percussion de cette cavite, par Avenbrugger. Paris: Migneret Publ. 1808: 486 p.
 9. Enersen O.D. (Ed.) Who named it? A dictionary of medical eponyms. URL: <http://www.whonamedit.com> (accessed 6 August 2018).
 10. Gubergits M.M. et al. Klinicheskaya diagnostika. Rukovodstvo dlya studentov i vrachej [Clinical Diagnosis. Guide for Students and Physicians]. Kiev: GMI USSR Publisher, 1939: 852 P. (in Russian) / Губергриц М.М. и соавт. Клиническая диагностика. Руководство для студентов и врачей. Киев.: ГМИ УССР, 1939. 852 с.
 11. Harrison's Principles of Internal Medicine. 14th edition (translated from English). Moscow: Praktika-McGraw — Hill Publishers (jointly), 2005; 4:1511–1518. (in Russian) / Внутренние болезни по Тинсли Р. Харрисону. Изд. 14-е. Пер. с англ. Том 4. М.: Практика — Мак-Гроу — Хилл (совместное издание), 2005. С. 1511–1518.
 12. Jonaš V. Klinicka kardiologie (translated from Czech). Praha: Zdravotnicke nakladatelstvi publisher, 1950: 748 P. (in Russian) / Йонаш В. Клиническая кардиология (пер. с чешск.). Прага: Государственное издательство медицинской литературы, 1966. 821 с.
 13. Laennec R. De l'auscultation mediate ou traite du diagnostic des maladies des poumon et du coeur. Paris: Brosson & Chaude Publ., 1819.
 14. Leared A. On the self-adjusting double stethoscope. *Lancet* 1856; 68:138.
 15. Magyar I. Differencial'naja diagnostika vnutrennih organov. Per. s veng. Tom I–II. [Differential Diagnostics of Internal Organs (translated from Hungarian)]. Budapest: Academiai Kiado Publishers, 1987; I–II: 1155 p. (in Russian) / Мадьяр И. Дифференциальная диагностика внутренних органов. Пер. с венг. Том I–II. Будапешт: Изд-во Академии наук Венгрии, 1987. 1155 с.
 16. Mil'kamanovich V.K. Metodicheskoe obsledovanie, simptomy i simptomokomplekxy v klinikei vnutrennih boleznej: Rukovodstvo dlya studentov i vrachej [Methodical Examination, symptoms and symptom complexes in clinics of internal diseases. Guide for students and physicians]. — Minsk: ООО "Polifakt-Al'fa" Publisher, 1994: 672 P. (in Russian) / Милькаманич В.К. Методическое обследование, симптомы и симптомокомплексы в клинике внутренних болезней: Руководство для студентов и врачей. Минск: Полифакт-Альфа, 1994. 672 с.
 17. Otto W., Hambach K., Treutler H. Medicinskaja poliklinicheskaja diagnostika. Per. s nem. [Outpatient medical diagnostics (translated from German)]. Moscow: Meditsina Publishers, 1979: 479 P. (in Russian) / Отто В., Хамбш К., Тройтлер Г. Медицинская поликлиническая диагностика. Пер. с нем. М.: «Медицина», 1979. 479 с.
 18. Sokol'sky G.I. Uchenie o grudnykh boleznyah [Doctrine of the Chest Diseases]. Moscow: Emperor's Moscow Univ. Publ., 1838 / Сокольский Г.И. Учение о грудных болезнях. М.: Изд-во Императорского Московского университета, 1838.
 19. Stroeve Y.I. K stoletiju so dnya rozhdeniya professora Alekseya Alekseevicha Kedrova [On the Centennial of Professor Aleksei Alekseevich Kedrov's birth]. *Meditsina — XXI vek* 2006; 4 (3): 110–112 (in Russian) / Строев Ю.И. К столетию со дня рождения профессора Алексея Алексеевича Кедрова. Медицина XXI век. 2006. N 4 (3). С. 110–112.
 20. Stroeve Y.I., Churilov L.P. Selected Lectures in Internal Medicine for M.D. Students. Part IV. Percussion in cardiovascular diseases. *Rus. Biomed. Res.* 2018; 3 (4): in press.
 21. Vasilenko V.H., Grebenev A.L., Golochevskaja V.S., Pletneva N.G., Sheptulin A.A. Propedevtika vnutrennih boleznej: Uchebnik. 5-e izdanie, pererabotannoe i dopolnennoe [Propedeutics of Internal Diseases. 5th Ed., amended]. Moscow: Meditsina Publishers, 2001: 592 P. (in Russian) / Василенко В.Х., Гребенев А.Л., Голочевская В.С., Плетнева Н.Г., Шептулин А.А. Пропедевтика внутренних болезней: Учебник. 5-е издание, переработанное и дополненное. М: Медицина, 2001. 592 с.
 22. Walker H.K., Hall W.D., Hurst J.W., eds. Clinical Methods: The History, Physical, and Laboratory Examinations. 3rd Ed. Boston: Butterworths; 1990. Available from: <https://www.ncbi.nlm.nih.gov/books/NBK201/>.
 23. Wilks, S. Evolution of the stethoscope, *Popular Science*, 1883; 22 (28): 488–491.
 24. URL: <http://old-kursk.ru/people/korotkow.html> (accessed 8 August, 2018) (in Russian) / Интернет-ресурс, URL: <http://old-kursk.ru/people/korotkow.html> (дата доступа: 8 августа 2018 г.).